

situation. In addition, we enabled endoscope base navigation on oblique-viewing endoscope as well and this lead to providing information from the two navigation systems during the entire span of the intranasal operation.

Our next step is to construct an information display method which the operator can grasp the inner structure of the surgical field more instinctively. In addition, we plan to improve the user interface of the system so the system can display the most adequate navigation information according to the various situations in the operation.

### A software tool for preoperative planning of implantable hearing devices

N. Gerber<sup>1</sup>, B. Bell<sup>1</sup>, M. Kompis<sup>2</sup>, C. Stieger<sup>1</sup>, M. Caversaccio<sup>1,2</sup>, S. Weber<sup>1</sup>

<sup>1</sup>University of Bern, ARTORG Center for Computer Aided Surgery, Bern, Switzerland

<sup>2</sup>University Hospital Bern, Department of ENT Surgery, Inselspital, Bern, Switzerland

**Keywords** Surgical-planning · Image-guided surgery · Hearing systems implantation · Rapid prototyping

### Purpose

Hearing aid implantation is one of the most delicate procedures in the domain of ENT surgery. It is typically achieved using a retromastoid microsurgical approach including a mastoidectomy to access the middle or inner ear. The direct acoustic cochlear stimulator (DACS) is an implanted active stapes prosthesis used for treatment of severe mixed hearing loss caused by advanced otosclerosis [1]. The implant consists of several mechanical components such as the stapes prosthesis, the actuator and a bone fixation system that have to be implanted with specific positioning constraints which ultimately affect global functionality. Thus, the mastoidectomy must be performed in a way that allows suitable placement of the implant whilst also enabling mounting of the system onto the surrounding mastoid surface.

DACS implantations are typically planned using available 3D tomographic medical image data, together with neuro-radiological expertise and without dedicated software tools. While computer assisted planning of hearing aids has been proposed in the past [2], no tool is available to position a multi-component implant. The complexity of the DACS implant further complicates the delicate implantation procedure. The creation of a suitable cavity in the mastoid is subject to the personal experience of the surgeon. Such implantation procedures are especially time-consuming and costly in cases with delicate anatomy such as a small facial recess.

To date, no approaches have been described in the literature, focusing on the implementation of end-to-end software tools for the planning of hearing aid implantation. While some teams are solely focusing on accuracy during the anatomy segmentation [3] prior to the planning process, others are interested in visualization aspects [4, 5].

In this contribution, we propose a dedicated software system for the planning of hearing aid implantations that incorporates general functionalities for the segmentation of anatomical structures as well as specific functionalities for the optimal positioning of all implant components. This tool enables surgeons to derive a precise understanding of the anatomical situation as well as concise plan of the implantation to be carried out. It is predicted that computer based planning will be associated with reduced OR time and lesser trauma due to smaller mastoidectomy.

### Materials and methods

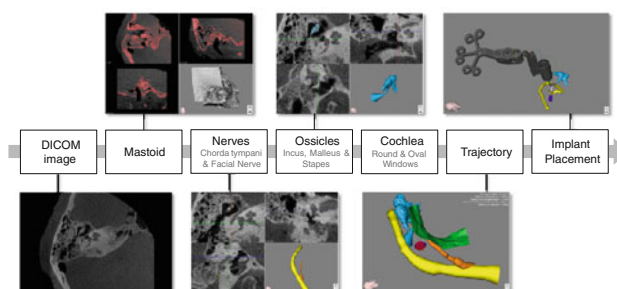
To support DACS implantations, a general planning software tool for otologic surgery, 'OtoPlan', has been extended to enable the planning of the implantation of DACS systems. Using the planning software,

the surgeon can segment all necessary anatomical details and position the components of a DACS implant with its fixation system in a 3D visualization context as part of a graphical user interface. Additionally, a virtual 3D plan can be exported and reproduced using rapid prototyping technology. Both the virtual visualization and the 3D physical model can serve as qualitative guiding means during the actual intervention.

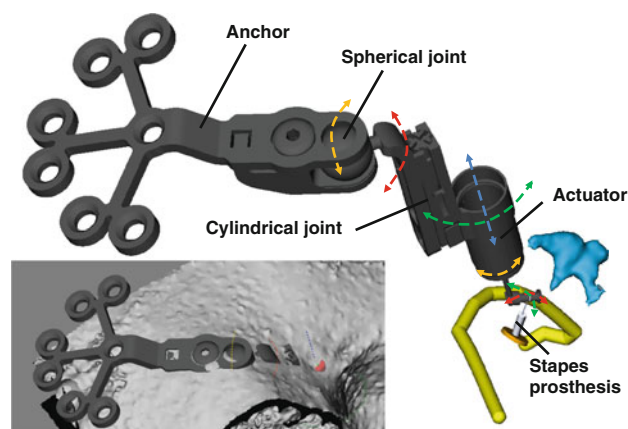
Initially, relevant anatomical structures, such as the mastoid, facial nerve, chorda tympani, external auditory canal, ossicles (including the incus, malleus and stapes), oval window and round window are identified and segmented using semi-automatic (i.e. region-growing, thresholding) and manual approaches (Fig. 1). Subsequently, surface models of all anatomical details are rendered.

The virtual implantation of a DACS implant is carried out as follows and is based on the model depicted in Fig. 2:

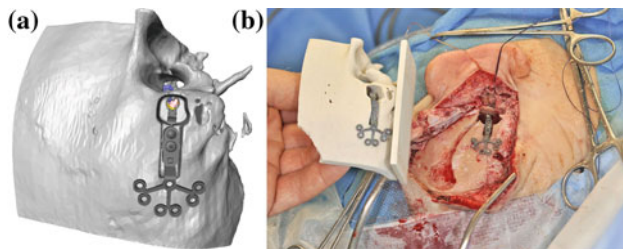
1. A conventional stapes prosthesis is automatically placed in the centre of the oval window. Its length can be selected within the typical range of 4–5 mm. The hook at the tip of the prosthesis can then be rotated around the oval window centre in two spherical directions, to allow for a suitable orientation.
2. The artificial incus of the DACS actuator is automatically aligned in the stapes prosthesis hook, as if the hook was crimped on it. The actuator can be rotated around its longitudinal axis. Thus, the effective crimp position (between the stapes implant and the actuator) can be defined.



**Fig. 1** Workflow of anatomy segmentation



**Fig. 2** Components of DACS implant planning and their respective degrees of motion (dotted arrows). Anatomy Facial nerve (yellow), oval window (orange disc), round window (purple disc), ossicles (light blue). Lower left Placement of the anchor on the mastoid surface



**Fig. 3** **a** 3D Model of the patient's anatomy and prospective planning of a DACS implants position and orientation and the volume of a mastoidectomy; **b** comparison of a completed implantation and the rapid prototyped plan

- Finally, the implant's fixation system is positioned. A cylindrical joint can be moved along or rotated around the actuator's axis controlling the depth and orientation of the proximal fixation system's part. A spherical joint links the later to the anchor as a final step. The anchor can thus be placed so that it aligns optimally with the mastoid surface using two spherical directions.

For each degree of freedom of the implant's components, discrete movements of one degree can be initiated via the graphical user interface. In a last step, a virtual mastoidectomy is created around the placed system. The plan including the middle ear anatomical models, the DACS implant and its fixation system (Fig. 2) is then transferred to a rapid prototyping machine (Z-Corp. USA) and a physical model is produced. The proposed computer-assisted planning system was evaluated in a single case of DACS implantation.

#### Results

Planning of the intervention, including segmentation of the relevant anatomical structures, using the computer system was completed in less than 20 min. With the aid of the virtual plan, the DACS device could be successfully positioned within the minimal mastoidectomy cavity planned preoperatively (Fig. 3a). The physical model (Fig. 3b) which was presented to the surgeon prior to and several times during the surgery, allowed for more intuitive comparison of the actual situs with the pre-planned model.

#### Discussion

We demonstrated the application of a patient-specific computer based planning system in one case of DACS implantation surgery. It was shown that precise preoperative planning can improve spatial awareness, which in turn allows for device placement in a minimally invasive mastoidectomy. To confirm results on a more statistically significant level, the system is being evaluated in ongoing larger clinical trials.

#### References

- Häusler R, Stieger C, Bernhard H, Kompis M (2008) "A novel implantable hearing system with direct acoustic cochlear stimulation". *Audiology & Neurotology* 13(4):247–256
- Dammann F, Bode A, Schwaderer E, Schaich M, Heuschmid M, Maassen MM (2001) "Computer-aided surgical planning for implantation of hearing aids based on CT data in a VR environment". *RadioGraphics* 21(1):183–191
- Noble JH, Warren FM, Labadie RF, Dawant BM (2008) "Automatic segmentation of the facial nerve and chorda tympani in CT images using spatially dependent feature values". *Medical Physics* 35(12):5375–5384
- Rodt T, Ratiu P, Becker H, Bartling S, Kacher DF, Anderson M, Jolesz FA, Kikinis R (2002) "3D visualisation of the middle ear and adjacent structures using reconstructed multi-slice CT datasets, correlating 3D images and virtual endoscopy to the 2D cross-sectional images". *Journal of Neuroradiology* 44(9):783–790

- Seemann M, Luboldt W, Haferkamp C, Bode A, Schäfer J, Allen CM, Dammann F, Plinkert P, Claussen CD (2000) "Hybrid 3D visualization and virtual endoscopy in cochlear implants". *RöFo* 172(3):238–243

#### Warning navigation system using real-time safe region monitoring for otology surgery

B. Cho<sup>1</sup>, M. Oka<sup>2</sup>, N. Matsumoto<sup>2</sup>, N. Matsumoto<sup>2</sup>, R. Ouchida<sup>3</sup>, J. Hong<sup>4</sup>, M. Hashizume<sup>1</sup>

<sup>1</sup>Kyushu University, Faculty of Medical Sciences, Fukuoka, Japan

<sup>2</sup>Kyushu University, Department of Otorhinolaryngology, Fukuoka, Japan

<sup>3</sup>Kyushu University, Faculty of Dental Sciences, City, Japan

<sup>4</sup>Daegu Gyeongbuk Institute of Science and Technology (DGIST), Department of Robotics Engineering, Daegu, Korea

**Keywords** Warning system · Otologic surgery · Feedback sound

#### Purpose

Otologic surgery requires a surgical navigation system with high accuracy to permit drilling into the temporal bone, which conceals important organs and to approach small anatomical targets without damage or injury [1]. During drilling of the temporal bone, even the most experienced and capable surgeons may have difficulty in identifying anatomical structures, particularly in revision surgery or patients with congenital malformations of the ear [2]. Although intraoperative facial nerve monitoring is a useful tool for prevention of iatrogenic facial nerve injury, it cannot be used to monitor other various organs. In addition, monitoring results may vary with the surgeon's experience and skill. In this study, we propose a novel surgical navigation system that warns the surgeon with audio feedback to protect important organs (e.g., the facial nerve) by using real-time monitoring of the safe region during drilling.

#### Methods

A free open source software 3D Slicer (Brigham Women's Hospital, Boston, MA, USA), installed on a Linux workstation, was employed as a software platform. Additional functions such as computing the safe margin and tracking the volume surface were developed and added to the 3D Slicer software. An optical position sensor, Polaris (NDI, Waterloo, ON, Canada) was used to detect and track the position of the surgical drill.

In this experiment, the facial nerve was chosen as a tracking target. In the surgical planning stage, to get 3D points on the surface of the facial nerve, surface rendering was performed from the segmented facial nerve of the computed tomography (CT) images. The data was saved in STL file format consisting of three 3D points and one normal vector and only 3D points from the surface of the facial nerve were extracted. Then, the surgeon classified the distances from the surface of the facial nerve with consideration of degree of risk: this study was set up 5, 3 and 1 mm. During drilling of the temporal bone, the closest distance between the drill tip and the surface of the facial nerve was computed in real time. When the drill tip approaches inside the safe distance that was set in the preoperative stage, the navigation system generates the different warning sounds according to the degree of risk.

To evaluate the effectiveness of the proposed system, we performed experiments in which a young and inexperienced surgeon drilled the temporal bone models while preserving the facial nerve with and without the navigation system (Fig. 1).

#### Results

The proposed navigation system was evaluated in phantom studies using models of the patients' temporal bones. A young and inexperienced surgeon drilled bone models 5 times with and without the navigation system respectively. The experiment with the warning navigation system ( $1.28 \pm 0.26$  mm) showed a significantly higher