



UNIVERSITÀ  
DEGLI STUDI  
FIRENZE

# FLORE

## Repository istituzionale dell'Università degli Studi di Firenze

### **Surgery of complex craniofacial defects: a single-step AM-based methodology**

Questa è la Versione finale referata (Post print/Accepted manuscript) della seguente pubblicazione:

*Original Citation:*

Surgery of complex craniofacial defects: a single-step AM-based methodology / Yary Volpe, Rocco Furferi, Lapo Governi, Francesca Uccheddu, Monica Carfagni, Federico Mussa, Mirko Scagnet, Lorenzo Genitori. - In: COMPUTER METHODS AND PROGRAMS IN BIOMEDICINE. - ISSN 0169-2607. - ELETTRONICO. - 165:(2018), pp. 225-233. [10.1016/j.cmpb.2018.09.002]

*Availability:*

This version is available at: 2158/1133974 since: 2021-03-30T16:07:30Z

*Published version:*

DOI: 10.1016/j.cmpb.2018.09.002

*Terms of use:*

Open Access

La pubblicazione è resa disponibile sotto le norme e i termini della licenza di deposito, secondo quanto stabilito dalla Policy per l'accesso aperto dell'Università degli Studi di Firenze (<https://www.sba.unifi.it/upload/policy-oa-2016-1.pdf>)

*Publisher copyright claim:*

Conformità alle politiche dell'editore / Compliance to publisher's policies

Questa versione della pubblicazione è conforme a quanto richiesto dalle politiche dell'editore in materia di copyright.

This version of the publication conforms to the publisher's copyright policies.

(Article begins on next page)



# Surgery of complex craniofacial defects: A single-step AM-based methodology

Yary Volpe<sup>a</sup>, Rocco Furferi<sup>a, \*</sup>, Lapo Governi<sup>a</sup>, Francesca Uccheddu<sup>a</sup>, Monica Carfagni<sup>a</sup>, Federico Mussa<sup>b</sup>, Mirko Scagnet<sup>b</sup>, Lorenzo Genitori<sup>b</sup>

<sup>a</sup> Department of Industrial Engineering of Florence, University of Florence (Italy), via di Santa Marta 3, 50139 Firenze, Italy

<sup>b</sup> Department of Pediatric Surgery, Meyer Children's Hospital, Viale Pieraccini 24, 50141 Florence, Italy

## ARTICLE INFO

### Article history:

Received 11 June 2018

Received in revised form 17 August 2018

Accepted 3 September 2018

Available online xxx

### Keywords:

Additive manufacturing

CAD

Cranium surgery

Image processing

## ABSTRACT

### Background and objective

The purpose of the present paper is to pave the road to the systematic optimization of complex craniofacial surgical intervention and to validate a design methodology for the virtual surgery and the fabrication of cranium vault custom plates. Recent advances in the field of medical imaging, image processing and additive manufacturing (AM) have led to new insights in several medical applications. The engineered combination of medical actions and 3D processing steps, foster the optimization of the intervention in terms of operative time and number of sessions needed. Complex craniofacial surgical intervention, such as for instance severe hypertelorism accompanied by skull holes, traditionally requires a first surgery to correctly “resize” the patient cranium and a second surgical session to implant a customized 3D printed prosthesis. Between the two surgical interventions, medical imaging needs to be carried out to aid the design the skull plate. Instead, this paper proposes a CAD/AM-based one-in-all design methodology allowing the surgeons to perform, in a single surgical intervention, both skull correction and implantation.

### Methods

A strategy envisaging a virtual/mock surgery on a CAD/AM model of the patient cranium so as to plan the surgery and to design the final shape of the cranium plaque is proposed. The procedure relies on patient imaging, 3D geometry reconstruction of the defective skull, virtual planning and mock surgery to determine the hypothetical anatomic 3D model and, finally, to skull plate design and 3D printing.

### Results

The methodology has been tested on a complex case study. Results demonstrate the feasibility of the proposed approach and a consistent reduction of time and overall cost of the surgery, not to mention the huge benefits on the patient that is subjected to a single surgical operation.

### Conclusions

Despite a number of AM-based methodologies have been proposed for designing cranial implants or to correct orbital hypertelorism, to the best of the authors' knowledge, the present work is the first to simultaneously treat osteotomy and titanium cranium plaque.

© 2018.

## 1. Introduction

### 1.1. Background and aims of the work

3D printed models give surgeons the opportunity to become familiar with the chosen approach and allow them to predict problems before entering the operation room. The most updated hospitals are already benefitting of the support of the 3D printing technologies for applications of maxillofacial and craniofacial, neurosurgery and reconstructive surgery clinical applications [1,2].

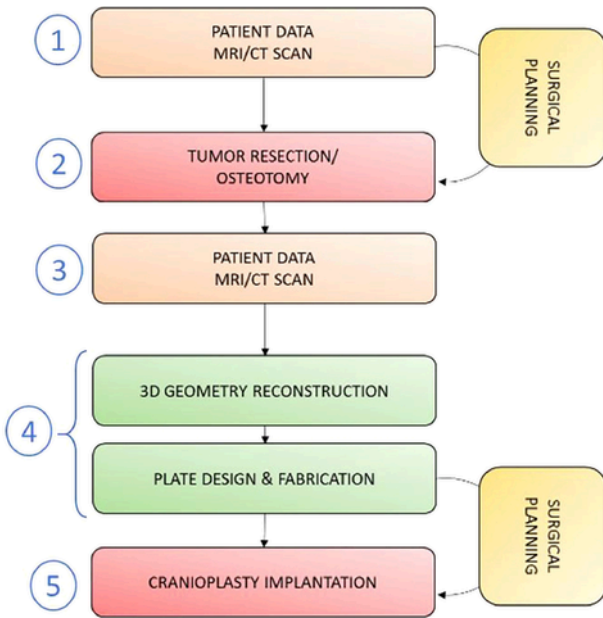
Virtual Surgical Planning and computer-aided design and manufacturing have gained popularity also in a wide array of craniofacial surgeries [3]; specific applications to pathologic conditions of the

head anatomic district was one of the first pioneering clinical applications of 3D printing in medicine [4,5].

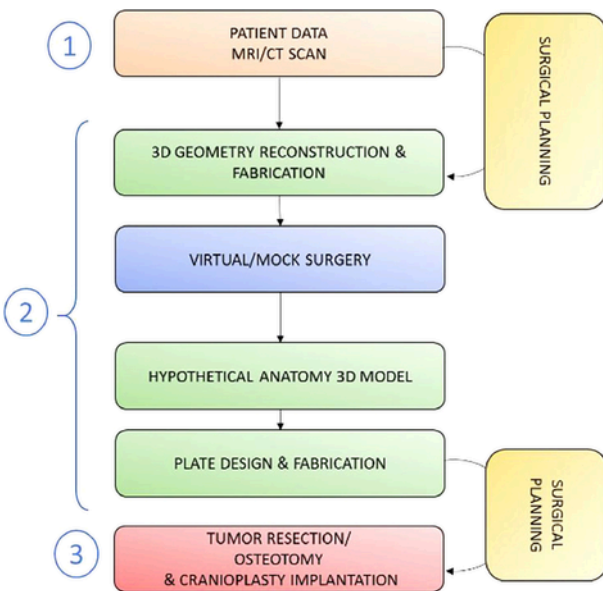
Physical replicas have been used during the harvesting bone grafts intervention design to repair facial clefts [6]; oral and maxillofacial surgeons have used 3D printing to plan for correction of orbital hypertelorism [7] and maxillary reconstruction [8]. Vascular models are also beneficial for surgical planning to highlight for instance intra-operative anatomic relationships [9]. The printed model can be used to determine the need for embolization, coiling, or clipping [10]. The model can also be employed to simulate the intervention and to define a surgical approach and strategy [11,12]. Preoperative, CAD/CAM-assisted planning was used also to simulate osteotomies [13]. The approach would permit for instance, complete macroscopic tumor resection in the oral cavity [14]. A prefabricated reconstruction plate in fact, allows pre-drilling the holes in the native mandible prior to the osteotomy to allow for a precise placement of the fibular graft.

\* Corresponding author.

Email address: [rocco.furferi@unifi.it](mailto:rocco.furferi@unifi.it) (R. Furferi)



**Fig. 1.** Traditional personalized approach using AM for designing and placing cranial plates.



**Fig. 2.** Proposed approach for simultaneous osteotomy/tumor resection and cranial plates placing.

In craniofacial surgery, 3D printed models have been used to assist pre-operative flap design in the treatment of Parry–Romberg syndrome [15] as well as in the design of osteotomy templates for skull tumorectomy [16].

The use of 3D technology to manufacture a custom implant have shown decreased complication rates and improved accuracy [17] compared to traditional approaches in which the patient anatomy is modeled to host the implant, and/or the implant is bended during the intervention.

During complicated surgeries like facial reconstruction after tumor resection [18], a significant amount of time is spent by the surgeons by contouring the titanium plates, while the patient is under

anesthesia. Metal additive manufacturing [19,20] offers the possibility of directly producing titanium or cobalt customized prostheses able to ensure better clinical outcomes.

The pediatric craniofacial population provides distinct challenges in the design of custom made implants mainly due to congenital deformities with varying degrees of bilateral dysmorphism [21,22], thus precluding the ability to plan reconstructions based on the healthy hemi-face [23]. Moreover, the defect can be caused by a trauma [24] or a tumor's resection [16] that requires a sequence of surgical procedures. Finally, surgical correction must allow for, and anticipate, further growth and development, often with the knowledge that dysmorphic relapse may occur [25].

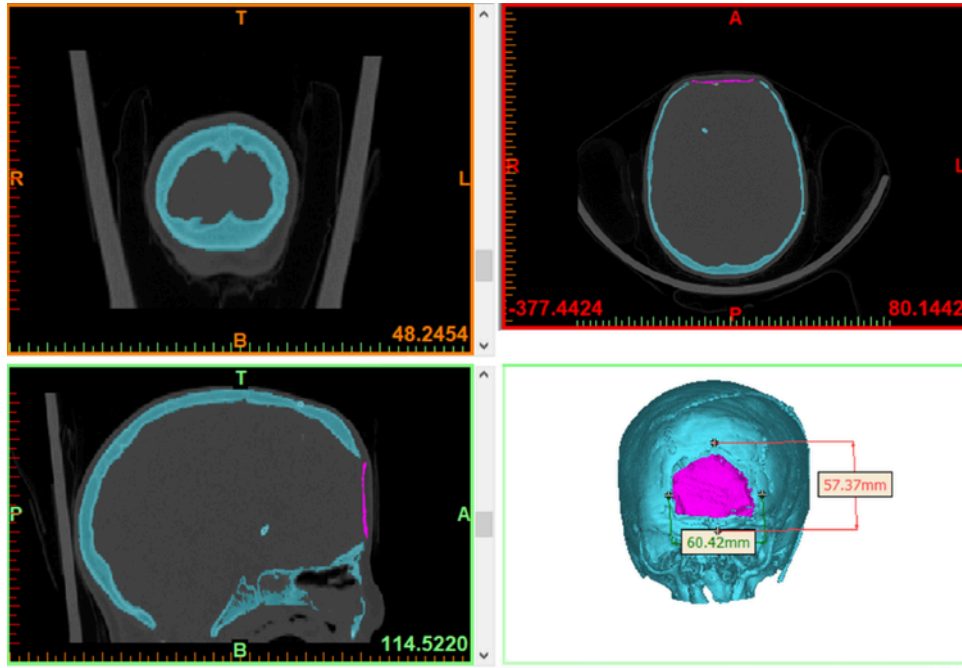
Orbital hypertelorism [26] is a craniofacial deformity characterized by an increased distance between both medial and lateral sides of the orbits. Most common causes are frontonasal defects, craniofacial gaps, encephalocele and syndromic or chromosomal disorders. Surgical correction of orbital hypertelorism in pediatric patients is still challenging and the treatment of choice widely relies on orbital mobilization or, if the malformation goes along with occlusal alterations, the indicated treatment is a facial bipartition with hemifacial rotation. A three-dimensional replica of the skull is advisable to help the surgeons to plan the surgical correction and, therefore, to reduce the time of surgery, accurately define the location of the osteotomies and pre-contouring the osteosynthesis material [27].

The correction of the hypertelorism, as well as the correction of other several craniofacial defects (including those caused by trauma or tumor resection) can leave in the patient some skull bone gaps that needs a cranioplasty to be corrected.

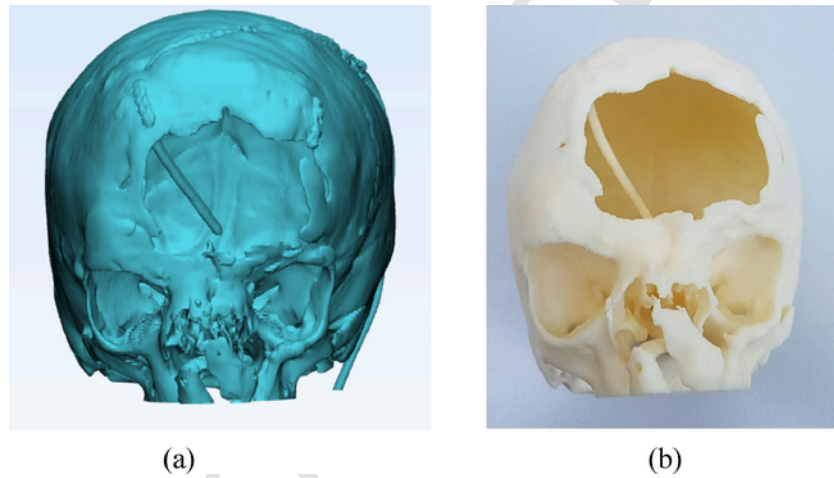
When a bone resection or mobilization is required to correct the defect, the cranial reconstruction cannot straightforwardly occur as part of the same procedure since a new cross-sectional imaging of the patient after the correction is needed to design the corrective skull plate. The cases of meningioma resection inspired the scientific community to define several single step-procedures [28,29]; the digitalization of the process of manufacturing a custom-made implant has indeed made it possible to produce accurately fitting implants with a minimum of intermediate steps, thus avoiding approximate reconstructions using conventional techniques or two-step procedures.

Authors in [30] explore the use of virtual surgical planning together through a CAD/CAM approach in complex pediatric craniofacial population. On the other hand, the use of 3D printed replica of the skull to be corrected has been reported in [27] in which a clinical case of a surgical correction of orbital hypertelorism planned by the 3D replica is described. The model was cut according to the established surgical procedure thus allowing the length and positioning of the osteotomies and to pre-contour osteosynthesis material required for the fixation of the mobilized bony segments.

Unfortunately, even when personalized AM-based approaches are carried out to design a cranium plate, there are several complex cases where the use of such a medical device is not sufficient. In particular, when patients are affected by a combination of “defects”, namely hypertelorism accompanied by missing bone in the cranium, a series of interventions are often needed to fully correct the deformity. A first step usually regards the bones mobilization; after the first intervention a new imaging of the patient is performed to both assess the correct repositioning of the structures and to eventually design a bone plate/implant according to the new bones shape in those cases in which a bone aperture persists after the repositioning. This means the need of at least two surgical operations. To overcome this issue, the present paper aims to define a methodology for the systematic optimization of complex craniofacial interventions thus reducing the overall surgical time. The proposed method is based on the idea that a



**Fig. 3.** CT scan obtained for the exemplificative case study used to describe the proposed procedure. Since the CT scan data are segmented, the plate to be removed is colored in pink while the segmented bone before surgery is colored in cyan. (For interpretation of the references to colour in this figure legend, the reader is referred to the web version of this article.)



**Fig. 4.** (a) 3D reconstructed model; (b) its physical counterpart obtained using the Fortus 450 machine.

combination of CAD and AM-based procedures to aid the surgeons in virtually or physically simulating the actual operation can help not only to plan the cuts and the positioning of the skull bones, but also to design the final plate without the need for a second round of surgery. Consequently, the surgeons could enter the surgical room only to perform both hypertelorism correction and plate placing in a single surgical intervention.

### 1.2. Traditional customized approaches

The traditional clinical approach to craniofacial patients to be corrected via bones mobilization consists in a sequence of clinical steps as illustrated in Fig. 1.

The *first step* consists in collecting a series of clinical images (CT/MRI) of the patient to be studied in order to plan the intervention. The surgical planning is performed basing on the cross-sectional images of the patient skull. During the intervention (*step two*) the head bones are rearranged to correct the defect.

Once performed the first intervention, as *third step*, the patient undergoes to a new series of MRI/CT scan. The analysis of the medical images is mainly performed to validate the outcome of the intervention. With the same dataset, the engineers can design (*step four*) a custom-made skull plate to be implanted in the following surgical session (*step five*).

The entire procedure, to be followed in case of complex craniofacial cases, envisage two surgical interventions and two CT scans of



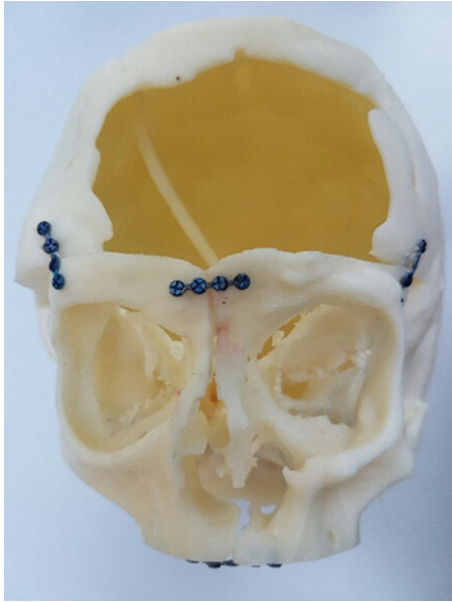


Fig. 5. Simulated osteotomy intervention on the mock for the selected case study.

the patient even when Virtual Surgical Planning or 3D printed skull replica are used [27,30,31].

2. Methods

The proposed approach simplifies the necessary technical and surgical steps and reduces the patient's exposure to ionizing radiation and to anesthesia in case of pediatric patients. This is addressed by diminishing the number of surgical sessions and the number of patient data acquisitions (see Fig. 2).

As in the traditional approach, the *first step* consists in collecting a series of clinical images (CT/MRI) of the patient to be studied. Such images are used to reconstruct the 3D virtual model of the skull to be corrected and to fabricate the physical replica. The *second step* envisages a simulated surgical intervention (e.g. osteotomy or tumor resection) that can be carried out either using a physical mock of the skull or virtually. In case a mock surgery is preferred by the medical staff, a mock of the skull is printed in 3D and the surgeon can operate on it simulating the actual intervention. The modified skull can be then re-converted in a virtual 3D model by using RE methods. Such a 3D

model represents the hypothesized anatomy of the patient after the osteotomy/tumor resection intervention and therefore on it is possible to design the cranial plate.

In case a virtual surgery is accomplished, within a CAD environment, the resulting file (i.e. a 3D model of the hypothesized anatomy of the patient after the osteotomy/tumor resection intervention) directly provides the basis for designing the cranial plate. Finally, the designed plate can be manufactured using metal-based 3D printing. The *third step* consists of the actual surgical intervention aiming at performing, at the same time, the osteotomy or tumor resection and the placement of the cranial plate.

In effect, by following such approach only one CT scan and one intervention are needed to obtain the same results as in the traditional approach. In fact, the design of the cranial plate is carried out after the first osteotomy/tumor resection operation has been effectively simulated on the mock/virtual model.

To better highlight the proposed method this is detailed with reference to a selected case study. A 7 year old girl was seen as an outpatient in June 2016. She had a craniofacial syndrome with hypertelorism and craniofacial cleft. A diagnosis of Goldhenar syndrome was made in the perinatal period. She was operated many times before in another Centre of Excellence for cranio-facial surgery. The deformation and the frontal overture have been previously corrected in her second year of life through an osteotomy of the frontal bones and the implantation of one central and two lateral resorbable plates. One year later, the patient underwent a new neurosurgical intervention to drain a hydrocephalus through the positioning of a VP shunt. The neurological status shows a mild psyco-motor delay.

The craniofacial anthropometric analysis shows a huge frontonasal bone defect with a consequent hypertelorism. The bone defect dimensions were transverse diameter of 60 mm and an antero-posterior diameter of 57 mm. Margins were jagged and the dura was trapped inside. Orbits were dystopic and nasal bone flattened and wide. There was marked frontal anomalies with cantal disproportion.

2.1. Patient imaging

As for the traditional clinical approach, also the proposed method starts from medical imaging. In detail, while both CT and MRI can be used to perform the diagnosis on the patient, the implemented method better performs using CT scanned data as an input for the subsequent phases. Since the main objective is to obtain a consistent 3D model representing the anatomy of interest of the patient, clinical practice for skull acquisition requires the CT scan to have at least a resolution

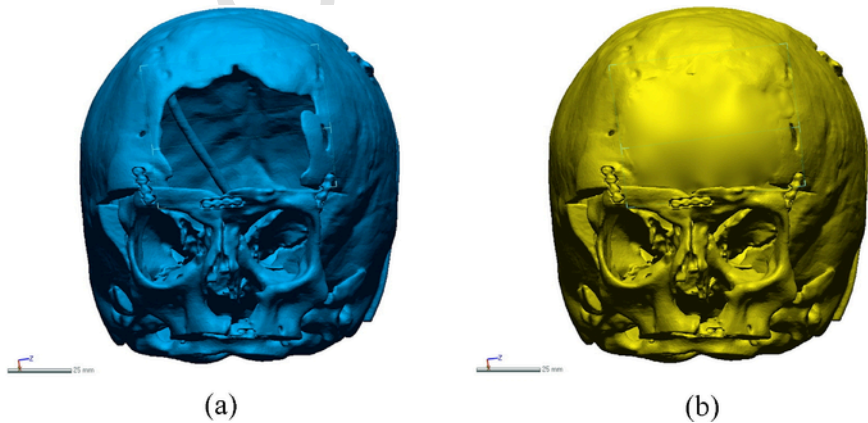
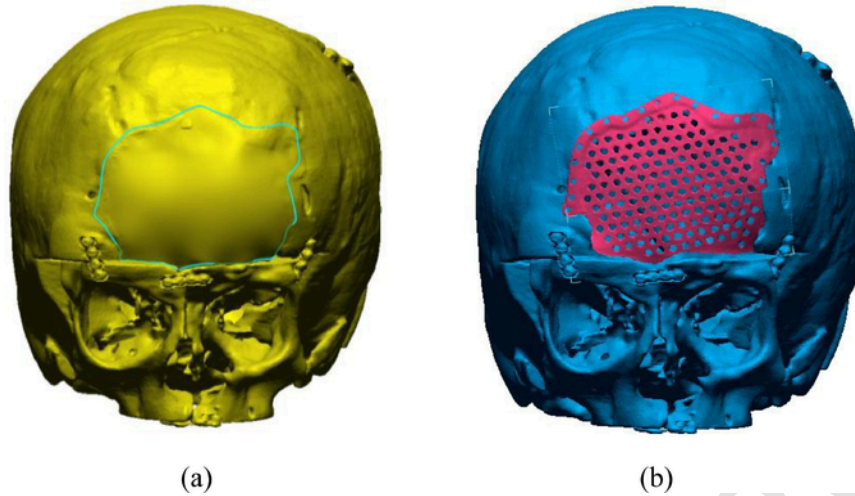



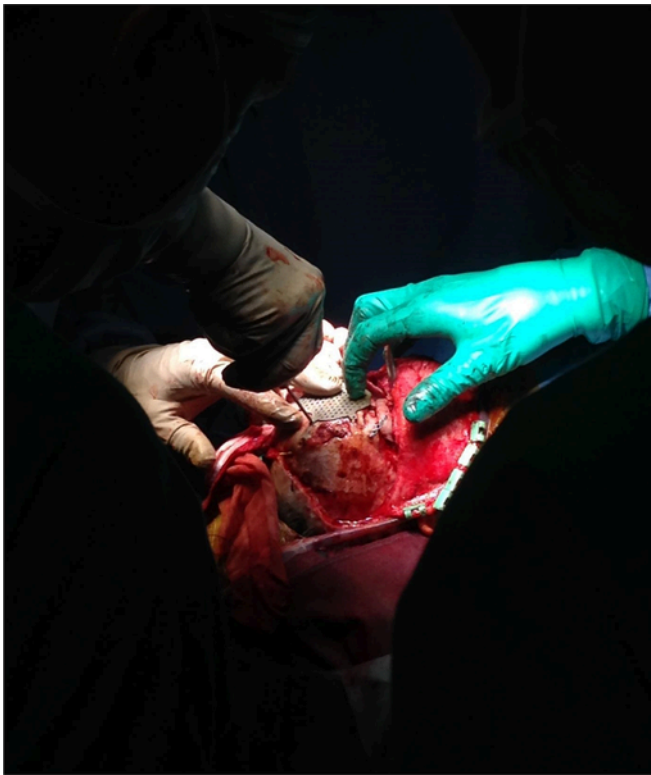
Fig. 6. (a) Digital model of virtually operated cranium; (b) cranium reconstructed using a surface interpolation based method.



**Fig. 7.** (a) Contours delimiting the cranial plate; (b) final model of the cranial plate virtually placed on the defected cranium.



**Fig. 8.** Cranial plate manufactured using the Arcam Q10 machine.



**Fig. 9.** Final placement of the titanium plate on the patient.

of  $512 \times 512$  pixels with xy spatial resolution in the range 0.4–0.8 mm and slice spacing in the range 0.4–2 mm. In the case study, the following parameters are set for CT scan: resolution equal to  $512 \times 512$  pixels, xy spatial resolution (pixel spacing) equal to 0.48 mm and slice spacing equal to 1 mm.

Referring to the selected case study, plain skull radiograph showed craniofacial anomalies with orbital malposition and central bone defect. The CT scan, moreover, showed the previous surgeries with many titanium plates (see Fig. 3). Orbital content was adequate and there were no optic nerve anomalies.

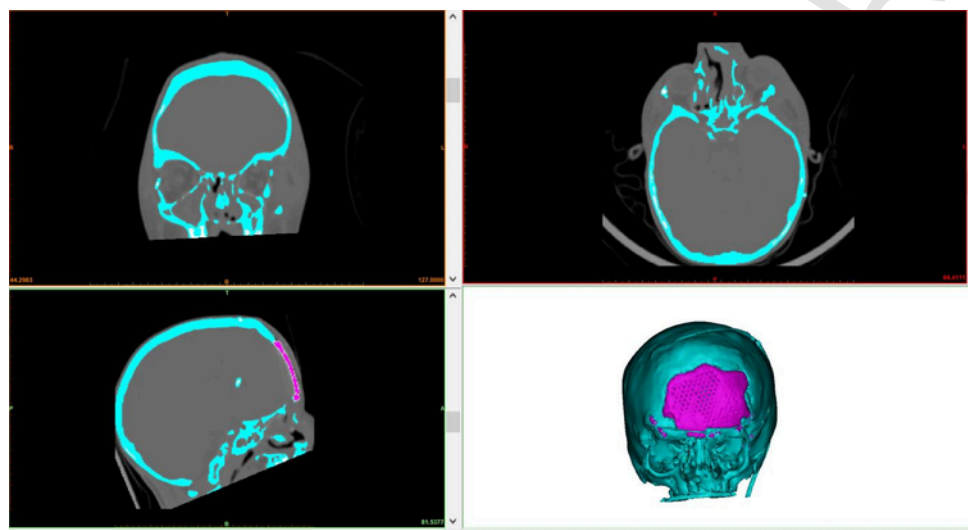
## 2.2. 3D geometry reconstruction of the defective skull

The 3D geometry reconstruction begins with the segmentation that consists in identifying and subdividing different anatomical structures or regions of interest (ROI) in the images resulting in a partition of the image pixels in non-overlapping regions, belonging to the same tissue class [32]. Segmented voxels [33] are processed using a marching cube algorithm [34] to obtain the 3D model. Since bones are clearly distinguishable in the CT scan from other head tissues, the segmentation can be performed automatically using a commercial 3D image processing software (e.g. Mimics, Materialise N.V., Leuven, Belgium), and by considering on each CT slice only the pixel above 226 Hounsfield units (HU) [35] (i.e. those corresponding to the bone tissue). In case no decimation is planned for the reconstruction, the multi-slices masks is required to have the same resolution as the CT images.

With reference to the case study, the old skull plate was separated from the skull bone, by performing a further segmentation from 1100 HU to 3071 HU. This choice was determined by verifying the

**Table 1**  
Comparison, in terms of patient benefits, between traditional and proposed approaches. Cost are assessed referring to Meyer Children's Hospital operating room (costs are in accordance with the ones reported in [41]).

Surgical operation time								
	# of surgeries		Anesthesia induction and surgical incision	Hypertelorism correction	Implant positioning	Suturing and awakening	Overall time	Surgical theater costs
Traditional approach	2	Surgery 1	2.5 h	6 h	–	1.5 h	10 h	18,000 €
		Surgery 2	2.5 h	–	1 h	1.5 h	6 h	10,800 €
		<b>Total</b>	Anesthesia induction and surgical incision	Hypertelorism correction	Implant positioning	Suturing and awakening	<b>16 h</b>	<b>28,800 €</b>
Proposed approach	1	Single-step surgery	2.5 h	6 h	1 h	1.5 h	10 h	18,000 €
		<b>Total</b>					<b>10 h</b>	<b>18,000 €</b>



**Fig. 10.** CT scan of the patient with corrected defect. In pink the new cranial plate; in cyan the segmented bone after surgery. (For interpretation of the references to colour in this figure legend, the reader is referred to the web version of this article.)

higher intensity of the gray color of the present titanium plate (colored in pink in Fig. 3). A further processing consisted in performing a Boolean subtraction between the skull segmentation mask and the plate segmentation mask, thus obtaining the entire skull segmentation without the plate. From the resulting multi-slice masks, 3D meshes were extracted using the Mimics’ “optimal quality” pre-defined mesh export setting. In Fig. 4a the final model of the patient skull is depicted.

### 2.3. Virtual planning and mock surgery

According to the proposed method, synthetized in Fig. 2, the surgical simulation can be carried out either through a virtual planning (i.e. completely digital) or through a mock surgery. In the first case, the 3D model of the patient skull can be managed within a CAD environment to decide the desired configuration of the patient anatomy after the osteotomy (or the tumor resection) has been carried out. This virtual intervention, obviously, requires CAD experts to be assisted by medical staff.

Quite the reverse, mock surgery consists in performing the surgical simulation on a physical replica (i.e. a mock) of the patient skull. Giving the widely known potential of Additive Manufacturing for creating realistic models of anatomical parts, such a mock can be easily created by using such a method. Therefore, the obtained 3D

meshes coming from the 3D geometry reconstruction of the defective skull can be exported to the STL file format to be further processed by using AM machines. To reduce costs, polymeric materials are preferred for this step; therefore, Fused Deposition Modelling (FDM) or Stereolithography (SLA) can fit the purpose.

In both cases (virtual and mock surgery), it is worth to mention that a set of patient-specific cutting guides conveying the correct cutting angles and positions can also be designed to aid the intervention. In case of virtual surgery, guides can be straightforwardly designed based on the digital model of the patient anatomy after the simulated intervention. In case of mock surgery, guides can be designed on the digital model coming from a 3D scan of the mock on which the intervention has been carried out. Such a set of guides, whose shape can be optimized on the basis of the cuts required to properly reposition the bones, can even be manufactured and used for the real surgical operation as, for instance, explained in [13] with reference to thoracic surgery. Since creating surgical guides is not a trivial task, a strong interaction between engineers and medical staff is required in this case.

With reference to the selected case study, due to the extreme complexity of the clinical case, mock surgery was preferred. Such choice allows the surgeons to gain not only a clear three-dimensional feeling of the osteotomies to perform, but also a tactile feedback of the real dimension of the maneuvers before entering the surgical room with-

out the need for this task of the engineers support. Moreover, the simulation on a mock does not require a CAD expert to guide the surgeon during the simulation. First, a Fortus 450 machine was used to produce the mock using the FDM technique and ABS-M30 as a material (see Fig. 4b). The finer allowable layer thickness (Z axis), equal to 0.127 mm, has been used to print the model. Parts are produced within an accuracy of  $\pm 0.127$  mm or  $\pm 0.0015$  mm/mm, whichever is greater. The selected material is characterized by a tensile strength equal to 26 MPa and a flexural strength equal to 48 MPa. Despite unrealistic with respect to the actual mechanical properties of the skull, such values are considered sufficient to simulate a physical intervention on the mock since they allow the use of surgical tools without compromising the integrity of the mock.

Then, the medical staff was able to simulate the intervention. The aim was the hypertelorism correction and the repair of the old cranioplasty that was detached from the bones and partially resorbed. Accordingly, the surgical procedure was entirely planned on the mock, used to determine the osteotomy lines, to decide where to raise bone grafts and how to shape them (see Fig. 5). The surgical planning, in fact, starts from measuring the desired distance between the lacrimal crests and allows the simulation of the surgical planning of the osteotomies and the skull shaping according to normal measures corresponding to the age of the patient. In this specific case study, the simulation was planned without the use of surgical guides because most of the osteotomies needed to be performed in areas covered by skin and muscles, so that the fixation of a surgical guide becomes impractical. Moreover, the only osteotomy affecting the shape of the cranial plate is the one performed horizontally above the supraorbital arches. Such an osteotomy can indeed be performed quite confidently (within a tolerance of 2–3 mm which is more than appropriate for the specific case) simply measuring an appropriate bone thickness between the upper part of the two supraorbital arches and the cutting line with no need of specific guides to replicate the osteotomy on the patient.

#### 2.4. Hypothetical anatomic 3D model

When the choice of the surgical simulation is referred to an entire virtual planning, the result of the simulation is directly a “corrected” 3D model of the skull of the patient. When a mockup is preferred to perform the simulation, the result consists of a corrected physical model. Since the design of the plate has to be performed on a digital model of the corrected cranium, a further reverse engineering-based step is needed to acquire 3D data from the modified mock. Data can be acquired either using a CT scan on the mock or, as an alternative, using commercial 3D scanners [37]. With reference to the case study a mockup was used to simulate the surgical intervention. Therefore, the “operated” plastic skull underwent a CT scan using the following specs: xy spatial resolution equal to 0.5 mm and slice spacing equal to 0.4 mm. This allowed to obtain the virtual model reported in Fig. 6a.

#### 2.5. Skull plate design and 3D printing

Once the mock/virtual surgery has been carried out by the surgeons, the outcome consists in a new configuration of the patient cranium, ready to be used for designing the cranial plate. The first important step for defining such a cranial implant consists of the digital reconstruction of the missing skull surface. Due to the importance of this task in the clinical practice, several studies have been proposed in literature, dealing with missing surface retrieval. As demonstrated in [38] most representative works fall under four main categories, depending on the reconstruction strategy adopted: (1) mirroring [17];

(2) surface interpolation [22]; (3) deformed template [6]; (4) slice-based reconstruction [1].

In the present work the selected method is based on surface interpolation, which pursues the generation of a smooth approximation of the skull shape across the defect region. Since the result is a mathematical surface characterized by a certain degree of continuity w.r.t. the defect edge, this approach guarantees the main advantage of ensuring the continuity at the boundary. Furthermore, the resulting surface is mathematically defined, so it could be evaluated at any desired resolution. The approach has a limitation for large holes (i.e. with area greater than 3–4% of the entire surface of the model [36]). In fact, the lack of constraints inside the defect region may lead to a too flat region in the inner side of the reconstructed cranial plate (i.e. the surface near to the defect margin has less reconstruction errors with respect to the center). For the selected case study, however, the overall surface of the skull hole after the virtual/mock surgery is approximately equal to 30 cm<sup>2</sup> and the entire outer surface has an area approximately equal to 800 cm<sup>2</sup>. Therefore, the surface interpolation can be accomplished without compromising the overall geometry of the cranium. In case the proposed method is to be applied to patients with larger defects, a good option is to adjust the reconstructed surface by using the approach provided in [20] where mirroring and surface interpolation are combined to strengthen the surface reconstruction.

The skull surface model of the reconstructed cranium obtained by applying the surface interpolation approach on the selected case study is in Fig. 6b. The procedure has been carried out by a CAD expert within a commercial Reverse Engineering software package (Geomagic® Design X). Nonetheless, strategies for automatic reconstruction of the missing skull surface will be implemented by authors in the near future.

Once the surface has been reconstructed, it is possible to draw the contours delimiting the cranial plate, taking into account both medical and engineering specifications. In detail, the contours should be smooth and should be at least 8 mm offset from the actual boundaries of the hole to assure the location of the screws to fix the plate on the patient (see for instance Fig. 7a). This offset also allows for safely compensating possible mismatch between the model (either physical or digital) used in the planning phase and the actual patient's anatomy. With this respect, common sources of variation, which however did not occur in the specific case study, are:

- bone remodeling which may have occurred in case of the evolution of a “growing fracture” (i.e. the opening of the dura madre that leaves the brain pushing against the border of the bone which can thereby evert in 1 or 2 months);
- imperfect bone segmentation in the recovery of the 3D model from tomographic images.

The contour obtained as explained above is, then, used to cut the mesh model of the reconstructed cranium thus limiting the mesh to a region of interest to be used for the subsequent phases. A free-form surface is then constructed on such a mesh. The surface is subsequently thickened (with a thickness value equal to 0.7 mm) and a pattern of hole with a diameter equal to 2 mm is used to allow fluid transfer and tissue to grow through it. Such values are in accordance with the ones provided in [21]. With reference to the case study, such a pattern is generated leaving a margin of 11 mm from the surfaces edges and using a pitch distance of 4.5 mm. The holes are generated using local normal directions of the surface as cutting direction. Moreover, along the surface margins another set of holes to arrange the fixing screws is generated. Holes have a diameter of 1.6 mm to use screws with diameter equal to 1.5 mm. In the proposed case study



screws holes are placed with a pitch equal to 8 mm and their center is at a distance of 3 mm from the surface contour.

In Fig. 7b the final model of the cranial plate, virtually placed on the defected cranium of the case-study patient, is depicted.

As soon as the 3D model of the cranial plate is designed, it is straightforward to build it by using Additive Manufacturing devices. In this work, the Electron Beam Melting (EBM) process was used to fabricate the skull plate, namely the Arcam Q10 machine. The used material is Ti6Al4V ELI Titanium Alloy, a gas-atomized powder with a particle size between 45 and 100  $\mu\text{m}$ , which proves to be suitable for medical applications due to its excellent biocompatibility especially when direct contact with tissue or bone is required [39]. Adopted layer thickness is equal to 50  $\mu\text{m}$ , the beam current is set to a value equal to 0.7 mA and the scan speed is set to 650 mm/s. In Fig. 8 the manufactured plate is shown. The weight of the implant for the patient of the selected case study is 12.20 g.

### 3. Results

As already mentioned, the proposed methodology has been tested on the case study presented in Section 2. Preoperative evaluation of the patient included: blood work-up, electrocardiogram, echocardiography, spirometry and plethysmography, which were all within normal range. The patient was therefore deemed suitable for surgery. On the day of the procedure, under general anesthesia, prophylactic antibiotic therapy was given.

The surgical bitragal scar due to the previous intervention was reopened. A careful dissection with the microscope of the subcutaneous space and removal of the previous attached frontal plates was then performed and the dura was detached from the skull base since no cerebral fluid fistulas covering the brain was present. Subsequently, an osteotomy of the entire orbits was bilaterally performed with the mobilization of the Bandeau according to the same procedure adopted in the mock-based simulation. The nasal bone and ethmoid were removed, and the titanium plates was finally placed to immobilize the rebuilt bandeau in the new position (see Fig. 9). Materials used in craniofacial surgery were selected to guarantee biocompatibility [40].

This single-step surgical intervention lasted 10 h (see Table 1), with no intraoperative complications observed. The actual surgical operation was carried out without the use of patient-specific cutting guides. Generally speaking, this may be a source of potential inaccuracies in actually reproducing the cranial hole to be covered by the plate. To reduce such a risk the surgery was performed paying particular attention to replicate as closely as possible the osteotomies performed on the mock used in the planning/training phase with specific reference to the horizontal supraorbital osteotomy (as explained in Section 2.3). This was also eased by keeping the model in the surgical room near the operator table so to make it possible for the surgeon to check it during the intervention.

Post-operative CT scan confirmed correct positioning of the titanium plate (see Fig. 10), thus demonstrating the effectiveness of the proposed methodology.

### 4. Discussion

Due to personalized design and manufacturing of the skull plate, the proposed methodology proves to decrease intra-operative time while decreasing the blood loss and handling trauma of the bone segments. As reported in Table 1 this single-step AM-based surgical intervention allowed, for the selected case study, an overall estimated reduction of time for the surgical operation equal to 6 h. More impor-

tant, especially when dealing with pediatric patients, the approach provides incredible benefits in terms of number of surgeries. In fact, the patient underwent only one surgery (where both hypertelorism and skull defect can be corrected) instead of two, thus further reducing the inherent risks of the operation. As a minor benefit, reducing number of operations and overall time in the surgical room allows also a cost reduction. Referring to the case study, the cost saving can be estimated equal to 10.800 € with respect to traditional approach, in accordance with the average costs reported in [41].

### 5. Conclusion

Traditional complex craniofacial surgical interventions often lack optimization in terms of operative time and number of sessions needed. Such issues have a major impact on pediatric population where a reduction of anesthesia and ionization doses is more beneficial than in adult population. The proposed procedure paves the way for a safer, faster and more effective complex cranial surgery comprising both osteotomies and cranial plate design, manufacturing and positioning. In particular, the complex defect is corrected in the same surgical session i.e. without the need of two subsequent surgical interventions. Nonetheless, the approach has a general validity for all cases where the high complexity of the surgical intervention demands for a preliminary planning/simulation. Some examples are malformations, severe skull trauma and tumor resections.

Despite a number of AM-based methodologies have been proposed for designing cranial implants [42] or to correct orbital hypertelorism [43], to the best of the authors' knowledge, the present work is the first to address complex operations where both pathologies are simultaneously treated by means of osteotomy (and consequent repositioning of orbital bones) and titanium cranium plaque. Future works will be addressed to test the procedure on a larger number of patients and to extend the proposed work to other complex surgical operations where the design of a personalized implant or medical device needs to be accompanied by other surgical procedures (e.g. maxillofacial field).

### Conflict of interest

The authors declare no conflict of interest.

### Uncited reference

[33].

### Supplementary materials

Supplementary material associated with this article can be found, in the online version, at doi:10.1016/j.cmpb.2018.09.002.

### References

- [1] F. Tomasello, A. Conti, D. La Torre, 3D printing in neurosurgery, *World Neurosurg.* 91 (2016) 633–634.
- [2] D. Hoang, D. Perrault, M. Stevanovic, A. Ghiassi, Surgical applications of three-dimensional printing: a review of the current literature & how to get started, *Ann. Transl. Med.* 4 (23) (2016).
- [3] S. Jaisinghani, N.S. Adams, R.J. Mann, J.W. Polley, J.A. Girotto, Virtual surgical planning in orthognathic surgery, *Eplasty* (2017), 17.
- [4] D.J. Bonda, S. Manjila, W.R. Selman, D. Dean, The recent revolution in the design and manufacture of cranial implants: modern advancements and future directions, *Neurosurgery* 77 (5) (2015) 814–824.
- [5] C.-Y. Liaw, M. Guvendiren, Current and emerging applications of 3D printing in medicine, *Biofabrication* 9 (2) (2017), 024102.

- [6] J. Wang, J.F. Liu, W. Liu, J.C. Wang, S.Y. Wang, L. Gui, Application of computer techniques in repair of oblique facial clefts with outer-table calvarial bone grafts, *J. Craniofac. Surg.* 24 (3) (2013) 957–960.
- [7] D.A. Mendonca, et al., Case series of three-dimensional printing technology applied in complex craniofacial deformity surgery, *J. Cleft Lip Palate Craniofac. Anomal.* 3 (2) (2016) 88.
- [8] P.H. de Moraes, S. Olate, M. Cantin, A.F. Assis, E. Santos, F.O. Silva, L.O. Silva, Anatomical reproducibility through 3D printing in cranio-maxillo-facial defects [Reproducibilidad anatómica a través de impresión 3D en defectos cranio-maxilo-faciales], *Int. J. Morphol.* 33 (3) (2015) 826–830.
- [9] D. Mitsouras, P. Liacouras, A. Imanzadeh, A.A. Giannopoulos, T. Cai, K.K. Kumamaru, V.B. Ho, Medical 3D printing for the radiologist, *Radiographics* 35 (7) (2015) 1965–1988.
- [10] H. Tenjin, Y. Okano, Training model for cerebral aneurysm clipping, *Interdiscip. Neurosurg.* 10 (2017) 114–118.
- [11] N. Martelli, et al., Advantages and disadvantages of 3-dimensional printing in surgery: a systematic review, *Surgery* 159 (6) (2016) 1485–1500.
- [12] V.N. Vakharia, N.N. Vakharia, C.S. Hill, Review of 3-dimensional printing on cranial neurosurgery simulation training, *World neurosurg.* 88 (2016) 188–198.
- [13] M. Carfagni, F. Facchini, R. Furferi, M. Ghionzoli, L. Governi, A. Messineo, et al., Towards a CAD-based automatic procedure for patient specific cutting guides to assist sternal osteotomies in pectus arcuatum surgical correction, *J. Comput. Des. Eng.* (2018).
- [14] E.L. Nyberg, A.L. Farris, B.P. Hung, M. Dias, J.R. Garcia, A.H. Dorafshar, W.L. Grayson, 3D-printing technologies for craniofacial rehabilitation, reconstruction, and regeneration, *Ann. Biomed. Eng.* 45 (1) (2017) 45–57.
- [15] G. Chai, A. Tan, C.A. Yao, et al., Treating Parry–Romberg syndrome using three-dimensional scanning and printing and the anterolateral thigh dermal adipofascial flap, *J. Craniofac. Surg.* 26 (2015) 1826–1829.
- [16] T. Oji, Y. Sakamoto, T. Miwa, Y. Nakagawa, K. Yoshida, K. Kishi, Usefulness of an osteotomy template for skull tumorectomy and simultaneous skull reconstruction, *J. Craniofac. Surg.* 27 (6) (2016) 1565–1567.
- [17] T.S. OH, W.S. Jeong, T.J. Chang, J.W. Choi, Customized orbital wall reconstruction using three-dimensionally printed rapid prototype model in patients with orbital wall fracture, *J. Craniofac. Surg.* 27 (2016) 2020e2024.
- [18] Azuma, M., Yanagawa, T., Ishibashi–Kanno, N., Uchida, F., Ito, T., Yamagata, K., ... & Sekido, M. (2014). Mandibular reconstruction using plates prebent to fit rapid prototyping 3-dimensional printing models ameliorates contour deformity. *Head Face Med.*, 10(1), 45.
- [19] N. Francaviglia, R. Maugeri, A.O. Contino, F. Meli, V. Fiorenza, G. Costantino, et al., Skull bone defects reconstruction with custom-made titanium graft shaped with electron beam melting technology: preliminary experience in a series of ten patients, In *Trends in Reconstructive Neurosurgery*, Springer, 2017137–141, Cham..
- [20] W.F. Yang, W.S. Choi, Y.Y. Leung, J.P. Curtin, R. Du, C.Y. Zhang, ..., Y.X. Su, Three-dimensional printing of patient-specific surgical plates in head and neck reconstruction: a prospective pilot study, *Oral Oncol.* 78 (2018) 31–36.
- [21] J.F. Isaza Saldarriaga, S. Correa Vélez, A. Cumplido Posada, B. Bedoya Henao, C.A. Torres Valencia, Design and manufacturing of a custom skull implant, *Am. J. Eng. Appl. Sci.* 4 (1) (2011) 169–174.
- [22] P.A. Trainor, J.T. Richtsmeier, Facing up to the challenges of advancing Craniofacial Research, *Am. J. Med. Genet. Part A* 167A (2015) 1451–1454.
- [23] M.M. Hatamleh, M. Cartmill, J. Watson, Management of extensive frontal craniofacial defects, *J. Craniofac. Surg.* 24 (2013) 2018–2022.
- [24] F.M. Marreiros, Y. Heuzé, M. Verius, C. Unterhofer, W. Freysinger, W. Recheis, Custom implant design for large cranial defects, *Int. j. comput. assist. radiol. surg.* 11 (12) (2016) 2217–2230.
- [25] S.T. Chen, C.J. Chang, W.C. Su, L.W. Chang, I.H. Chu, M.S. Lin, 3-D titanium mesh reconstruction of defective skull after frontal craniectomy in traumatic brain injury, *Injury* 46 (1) (2015) 80–85.
- [26] J.U. Pucci, B.R. Christophe, J.A. Sisti, E.S. Connolly Jr., Three-dimensional printing: technologies, applications, and limitations in neurosurgery, *Biotechnol. Adv.* 35 (5) (2017) 521–529.
- [27] P. Tessier, The conjunctival approach to the orbital floor and maxilla in congenital malformation and trauma, *J. Maxillofac. Surg.* 1 (1973) 3–8.
- [28] M. Engel, J. Hoffmann, G. Castrillon-Oberndorfer, C. Freudsperger, The value of three-dimensional printing modelling for surgical correction of orbital hypertelorism, *Oral Maxillofac. Surg.* 19 (1) (2015) 91–95.
- [29] C.E. Broeckx, T.J. Maal, R.D. Vreeken, R.R. Bos, M. ter Laan, Single-step resection of an intrasosseous meningioma and cranial reconstruction, *World Neurosurg.* 108 (2017) 225–229.
- [30] <http://www.renishaw.com/en/digital-evolution-of-cranial-surgery-38602>. Accessed on 23 February 2018.
- [31] R. Gray, A. Gougoutas, V. Nguyen, J. Taylor, N. Bastidas, Use of three-dimensional, CAD/CAM-assisted, virtual surgical simulation and planning in the pediatric craniofacial population, *Int. J. Pediatr. Otorhinolaryngol.* 97 (2017) 163–169.
- [32] H.M. Hidalgo, G.W. Romo, R.T.R. Estolano, Stereolithography: a method for planning the surgical correction of the hypertelorism, *J. Craniofac. Surg.* 20 (5) (2009) 1473–1477.
- [33] F. Uccheddu, M. Carfagni, L. Governi, R. Furferi, Y. Volpe, E. Nocerino, 3D printing of cardiac structures from medical images: an overview of methods and interactive tools, *Int. J. Interactive Des. Manuf. (IJIDeM)* (2017) 1–13.
- [34] W.E. Lorensen, H.E. Cline, Marching cubes: a high resolution 3D surface construction algorithm, *ACM SIGGRAPH Computer Graphics*, 21, ACM, 1987, August163–169.
- [35] E.E. Özşavaş, Z. Telatar, B. Dirican, Ö. Sağer, M. Beyzadeoğlu, Automatic segmentation of anatomical structures from CT scans of thorax for RTP, *Comput. Math. Methods Med.* (2014 Article ID 472890, 1-14).
- [36] E. Pérez, S. Salamanca, P. Merchán, A. Adán, A comparison of hole-filling methods in 3D, *Int. J. Appl. Math. Comput. Sci.* 26 (4) (2016) 885–903.
- [37] M. Carfagni, R. Furferi, L. Governi, M. Servi, F. Uccheddu, Y. Volpe, On the performance of the Intel SR300 depth camera: metrological and critical characterization, *IEEE Sens. J.* 17 (14) (2017) 4508–4519.
- [38] F. Buonamici, R. Furferi, L. Genitori, L. Governi, A. Marzola, F. Mussa, Y. Volpe, Reverse engineering techniques for virtual reconstruction of defective skulls: an overview of existing approaches, *Comput. Aided Des. Applic.* (16) (1), 2018), 103–112.
- [39] O. Cansizoglu, O. Harrysson, D. Cormier, H. West, T. Mahale, Properties of Ti–6Al–4V non-stochastic lattice structures fabricated via electron beam melting, *Mater. Sci. Eng.: A* 492 (1-2) (2008) 468–474.
- [40] F. Bano, Biomaterials and implants for orbital floor repair, *Acta Biomater.* 7 (9) (2011) 3248–3266.
- [41] A. Tarsitano, S. Battaglia, S. Crimi, L. Ciocca, R. Scotti, C. Marchetti, Is a computer-assisted design and computer-assisted manufacturing method for mandibular reconstruction economically viable?, *J. Craniomaxillofac. Surg.* 44 (7) (2016) 795–799.
- [42] X. Chen, L. Xu, X. Li, J. Egger, Computer-aided implant design for the restoration of cranial defects, *Sci. Rep.* 7 (1) (2017) 4199.
- [43] M. Engel, J. Hoffmann, G. Castrillon-Oberndorfer, C. Freudsperger, The value of three-dimensional printing modelling for surgical correction of orbital hypertelorism, *Oral Maxillofac. Surg.* 19 (2015) 91–95.