



DTI and MTR abnormalities in schizophrenia: Analysis of white matter integrity

Citation

Kubicki, M., H. Park, C.F. Westin, P.G. Nestor, R.V. Mulkern, S.E. Maier, M. Niznikiewicz, et al. 2005. "DTI and MTR Abnormalities in Schizophrenia: Analysis of White Matter Integrity." *NeuroImage* 26 (4) (July): 1109–1118. doi:10.1016/j.neuroimage.2005.03.026.

Published Version

doi:10.1016/j.neuroimage.2005.03.026

Permanent link

<http://nrs.harvard.edu/urn-3:HUL.InstRepos:28625115>

Terms of Use

This article was downloaded from Harvard University's DASH repository, and is made available under the terms and conditions applicable to Other Posted Material, as set forth at <http://nrs.harvard.edu/urn-3:HUL.InstRepos:dash.current.terms-of-use#LAA>

Share Your Story

The Harvard community has made this article openly available.
Please share how this access benefits you. [Submit a story](#).

[Accessibility](#)

Published in final edited form as:

Neuroimage. 2005 July 15; 26(4): 1109–1118. doi:10.1016/j.neuroimage.2005.03.026.

DTI and MTR abnormalities in schizophrenia: Analysis of white matter integrity

M. Kubicki^{a,b,*}, H. Park^{a,b,f}, C.F. Westin^b, P.G. Nestor^c, R.V. Mulkern^d, S.E. Maier^e, M. Niznikiewicz^a, E.E. Connor^a, J.J. Levitt^a, M. Frumin^a, R. Kikinis^b, F.A. Jolesz^b, R.W. McCarley^a, and M.E. Shenton^{a,b}

^aClinical Neuroscience Division, Laboratory of Neuroscience, Boston VA Healthcare System-Brockton Division, Department of Psychiatry, Harvard Medical School, Brockton, MA 02301, USA

^bSurgical Planning Laboratory, MRI Division, Department of Radiology, Brigham and Women's Hospital, Harvard Medical School, Boston, MA 02301, USA

^cDepartment of Psychology, University of Massachusetts, Boston, MA 01003, USA

^dDepartment of Radiology, Children's Hospital, Harvard Medical School, Boston, MA 02301, USA

^eDepartment of Radiology, Brigham and Women's Hospital, Harvard Medical School, Boston, MA 02301, USA

^fDepartment of Diagnostic Radiology, Yonsei University, College of Medicine, Seoul, Republic of Korea

Abstract

Diffusion tensor imaging (DTI) studies in schizophrenia demonstrate lower anisotropic diffusion within white matter due either to loss of coherence of white matter fiber tracts, to changes in the number and/or density of interconnecting fiber tracts, or to changes in myelination, although methodology as well as localization of such changes differ between studies. The aim of this study is to localize and to specify further DTI abnormalities in schizophrenia by combining DTI with magnetization transfer imaging (MTI), a technique sensitive to myelin and axonal alterations in order to increase specificity of DTI findings. 21 chronic schizophrenics and 26 controls were scanned using Line-Scan-Diffusion-Imaging and T1-weighted techniques with and without a saturation pulse (MT). Diffusion information was used to normalize co-registered maps of fractional anisotropy (FA) and magnetization transfer ratio (MTR) to a study-specific template, using the multi-channel daemon algorithm, designed specifically to deal with multi-directional tensor information. Diffusion anisotropy was decreased in schizophrenia in the following brain regions: the fornix, the corpus callosum, bilaterally in the cingulum bundle, bilaterally in the superior occipito-frontal fasciculus, bilaterally in the internal capsule, in the right inferior occipito-frontal fasciculus and the left arcuate fasciculus. MTR maps demonstrated changes in the corpus callosum, fornix, right internal capsule, and the superior occipito-frontal fasciculus bilaterally; however, no changes were noted in the anterior cingulum bundle, the left internal capsule, the arcuate fasciculus, or inferior occipito-frontal fasciculus. In addition, the right posterior cingulum bundle showed MTR but not FA changes in schizophrenia. These findings suggest that, while some of the diffusion abnormalities in schizophrenia are likely due to abnormal coherence, or organization of the fiber tracts, some of these abnormalities may, in fact, be attributed to or coincide with myelin/axonal disruption.

Keywords

Diffusion tensor imaging; Magnetization transfer ratio; Schizophrenia; White matter integrity

Introduction

Findings in schizophrenia research confirm the presence of structural brain abnormalities and further suggest the involvement of a large number of brain regions, many of which are highly functionally related. The idea that schizophrenia might be a disorder characterized by abnormal connections between these regions dates back to the beginning of this century, when both Wernicke (1905) and Kraepelin (1919/1971) suggested the importance of fronto-temporal white matter connections in the neuropathology of this disorder. This hypothesis has been refueled by more recent brain investigations involving various imaging methods (Friston and Frith, 1995; McGuire and Frith, 1996; Weinberger, 1987, 1992).

However, despite many MRI findings of gray matter abnormalities in schizophrenia, there is no compelling post-mortem evidence to suggest neuronal loss in these brain regions. Instead, microscopic post-mortem investigations point to abnormalities of neuronal cytoarchitecture, with evidence for reduction in neuronal size, dendritic spine density, dendritic length, and in synaptic proteins (for a review, see Harrison, 1999). In addition, recent neuropathological studies suggest that glial cells are abnormal in schizophrenia (Uranova et al., 2001). Of particular note here, both microscopic (Uranova et al., 2001) and genetic studies (Hakak et al., 2001) demonstrate oligodendrocyte abnormalities in schizophrenia; these cells play a major role in protecting neuronal axons traveling within white matter fiber tracts by forming myelin sheaths. It is also noteworthy that glial cells play an important role in cellular protection and support of neuronal cell metabolism (Cotter et al., 2001), as well as play an important role in both neuronal migration and synaptic function (including glutamatergic and NMDA regulation—observed to be abnormal in schizophrenia (for a review, see Tamminga, 1998; Coyle et al., 2002; Harrison and Owen, 2003). Thus, it is possible that glial abnormalities could lead to the reduced neuronal size, reduced levels of synaptic proteins, as well as to neurotransmission and functional abnormalities (including functional disconnectivity), all of which are observed in schizophrenia. These data argue that methods sensitive to white matter abnormalities, especially of fiber tracts, are critical to understanding the role of abnormal white matter in the neuropathology of schizophrenia.

MR DTI, thought to be an indicator of the fiber tract integrity, reflecting coherence, organization and/or density of the fiber bundles in white matter regions of the brain, is one of the relatively newer, promising in vivo methods that have made it possible to investigate white matter abnormalities in schizophrenia. Findings published to date reveal a decrease of diffusion anisotropy in schizophrenia, although there are also several studies describing negative findings (for a review, see Kubicki et al., 2002a; Lim and Helpert, 2002). Differences in acquisition and analysis methods could account for the inconsistent findings.

Approximately half of the studies published thus far have used a region of interest (ROI) analysis method, where findings have revealed changes in the cingulum bundle, uncinate and arcuate fasciculi, corpus callosum, and whole frontal and temporal white matter. A limitation of this approach is the difficulty in defining fiber bundle boundaries. More specifically, ROI analyses involve either sampling over the 2D square ROI that includes, but is not limited to, the particular fiber bundle, or it involves thresholding a portion of the fiber bundle (also in 2D) based on the directional information, in which case-dependent variables (i.e., eigenvalues) that are employed to define the fiber tract boundaries are subsequently used to calculate the FA

maps, which may bias the results. Moreover, neither of these approaches are very reliable or reproducible due to their sensitivity to image distortions and partial volume effects.

The other half of the DTI schizophrenia studies (Ardekani et al., 2003; Buchsbaum et al., 1998; Foong et al., 2002) have investigated anisotropy using a voxel based analysis approach (Ashburner and Friston, 2000; Good et al., 2001; Rugg-Gunn et al., 2001; Watkins et al., 2001). This method can be applied without a priori hypotheses, and it allows for the investigation of the whole brain at once. This approach, however, also has several limitations. For example, in order to compare groups on a voxel-by-voxel basis, all of the structures of one individual's brain need to be co-registered as precisely as possible to the template brain. Unfortunately, structural T1/T2-weighted images, or scalar FA maps used for the co-registration, do not possess the information about orientation and magnitude of directional diffusion, and thus this type of analysis applied to the DTI data does not attempt to match fiber bundles but instead registers only the outer boundaries of the white matter. In effect, small fiber bundles are not precisely registered.

One possible approach to minimize this problem is to use the directional tensor information for normalization purposes, trying to match more precisely the shape, but also the direction, of the fiber tracts existing in white matter, before the anisotropy within the registered voxels is compared.

The goal of this study is to investigate microstructural white matter abnormalities in schizophrenia, using two complementary imaging techniques—DTI and MTR. The voxel-by-voxel between-group comparison will be performed after higher order multi-channel spatial normalization of both tensor and MTR data (Guimond et al., 2001, 2002; Park et al., 2003, 2004).

As the specificity of the DTI method is unknown due to a lack of validation studies, the microstructural abnormalities underlying the diffusion differences are also unknown. Abnormalities detected using DTI-based measures of anisotropy are usually taken to be indicative of abnormalities in coherence/organization/direction of white matter fibers, however, other candidate processes include changes in the number and/or density of interconnecting fiber tracts as well as changes in myelination. Although myelination is not essential for diffusion anisotropy of nerves (Beaulieu and Allen, 1994; Huppi et al., 1998), myelin is generally assumed to be the major barrier to diffusion in white matter tracts. Furthermore, as mentioned above, several studies implicate the role of myelin abnormalities in schizophrenia (Benes et al., 1986; Hakak et al., 2001; Hyde et al., 1992; Uranova et al., 2001, 2004).

Thus, in this study, we combine DTI with another MRI method, based on magnetization transfer (MT) properties of brain tissue. Magnetization transfer ratio (MTR) is a measure derived from the MT technique that is selectively sensitive to restricted protons, associated with macromolecules and membranes in biological tissues (such as cholesterol or glucocerebrosides) otherwise not detectable using conventional MR techniques (due to their too short T2 relaxation times (Grossman et al., 1994)). The magnitude of the signal detected by this technique depends directly on both the amount and the states of macromolecules in the tissue. In brain parenchyma, myelin proteins may account for a substantial portion of the observed effect. It has been demonstrated that this technique is very sensitive to white matter changes, e.g., in multiple sclerosis (even when the MRI is negative (Ge et al., 2002)), Alzheimer's disease, and brain tumors (Grossman et al., 1994), as well as demonstrating more correlations with clinical status and cognitive dysfunction in MS subjects than any other structural MR measurements (Rovaris et al., 2000). In addition, schizophrenia studies (Bagary et al., 2003; Foong et al., 2000, 2001) demonstrate lower MTR in schizophrenic subjects

compared to controls. Thus, while DTI provides a unique opportunity to investigate the integrity of white matter fiber tracts in schizophrenia, the addition of MTR affords a unique opportunity to differentiate between white matter fiber tract abnormalities that are due to alterations in axonal coherence, density or thickness (when only FA is affected), and myelin sheath thickness or composition, when both FA and MTR are abnormal.

Here, the same registration algorithm has been also applied to structural MR, DTI, and MTR images. This co-registration of multiple images made it possible for us to compare results of the DTI and MTR between patients with schizophrenia and controls, which, in turn, allowed us to characterize better white matter structural abnormalities in schizophrenia.

Materials and methods

Subjects

Twenty one patients with schizophrenia were recruited from inpatient, day treatment, outpatient, and foster care programs at the VA Boston Healthcare System, Brockton, MA. SCID-P interviews were administered to make DSM-IV diagnoses, and SCID-NP interviews were completed for 26 normal comparison subjects.

Comparison subjects were recruited from the general community and group-matched to patients on age, sex, handedness, and parental social economic status (PSES).

Inclusion criteria for all subjects were: right-handedness; ages between 18 and 55 years; no history of electroconvulsive shock treatment; no history of neurological illness; no alcohol or drug dependence in the last 5 years and no abuse in the past year; verbal IQ above 70; no medication with deleterious effects on neurological or cognitive functions; and, an ability and desire to cooperate with the procedures confirmed by written informed consent. In addition, normal comparison subjects were screened to exclude individuals who had a first degree relative with an Axis I disorder. The study was approved by the local IRB committee, and all subjects signed informed consent prior to study participation.

MRI protocol

For all the subjects, DTI data were acquired using line scan diffusion imaging (LSDI), a protocol that can be implemented on conventional MR scanners (Gudbjartsson et al., 1996; Maier et al., 1998). In contrast to single-shot echo-planar imaging methods, LSDI is not as sensitive to susceptibility variations and chemical shift effects. As such, the superior quality of line scan diffusion images is particularly evident in areas near large bone structures such as orbits, maxillary cavities, temporal lobe, and the inferior fossa, where the geometry of the brain is not distorted as in EPI methods. The latter is especially important when whole brain co-registration methods are being applied to the diffusion images. Of note, data obtained in an experiment comparing LSDI and single-shot EPI have shown that LSDI data, with respect to reproducibility, were comparable to 4 repetition single shot EPI, with even better Signal to Noise Ratio than the EPI protocol (Kubicki et al., 2004).

MR diffusion scans were performed with a quadrature head coil on a 1.5 T GE Echospeed system (General Electric Medical Systems, Milwaukee, WI), which permits maximum gradient amplitudes of 40 mT/m. Coronal LSDI scans were acquired perpendicular to both the AC–PC line and interhemispheric fissure. To increase the precision of the acquisition alignment, instead of one 3D localizer, a set of three 2D T1-weighted localizers (sagittal, axial oblique aligned to the anterior commissure–posterior commissure (AC–PC) line, and another sagittal oblique aligned to the interhemispheric fissure) were acquired. Finally, the last sagittal oblique T1W image served as the localizer for the LSDI coronal scans. For each section, six images with high (1000 s/mm²) diffusion-weighting along six non-collinear directions [e.g., relative

amplitudes, $(G_x, G_y, G_z) = \{(1,1,0), (0,1,1), (1,0,1), (-1,1,0), (0,-1,1), (1,0,-1)\}$ and two with low (5 s/mm^2) diffusion-weighting have been collected. The following scan parameters were used: rectangular FOV (field of view) $220 \times 165 \text{ mm}^2$; 128×128 scan matrix (256×256 image matrix); slice thickness 4 mm; interslice distance 1 mm; receiver bandwidth $\pm 4 \text{ kHz}$; TE (echo time) 64 ms; effective TR (repetition time) 2592 ms; scan time 60 s/slice section. A total of 31–35 coronal slices covering the entire brain (depending upon brain size) were acquired. The total scan time was 31–35 min. After reconstruction, the diffusion-weighted images were transferred to a SUN workstation, where eigenvalues, eigenvectors, and fractional anisotropy (FA) maps of the diffusion tensor were calculated. Motion-related artifact maps were also constructed (Maier et al., 1998).

To create MTR (magnetization transfer ratio) maps, which represent the loss of the signal due to the magnetization transfer (MT) effect, two additional separate scans with and without an additional RF magnetization transfer (MT) pulse were acquired. The same image resolution, slice thickness, slice orientation, and slice number as for DTI were used, and the scan parameters were: TE 30 ms, TR 600 ms. Bandwidth offset for MT pulse was 1200 Hz. Scan time for T1 was 2.55 min, and for T1 with MT, 5.12 min.

Finally, to achieve reliable white matter segmentation masks, a series of 124 contiguous coronal images were acquired using an SPGR sequence with the following parameters: TR = 35 ms, TE = 5 ms, 45 degree flip angle, 24 cm^2 field of view, NEX = 1.0 (number of excitations), matrix = 256×256 (192 phase-encoding steps). The voxel (volume of pixel) dimensions were $0.94 \times 0.94 \times 1.5 \text{ mm}$.

Image analysis

Before performing statistical analysis, individual subjects' images underwent multiple preprocessing steps. First, both series of T1-weighted images, with and without the MT pulse, were co-registered together using the mutual information registration algorithm. This procedure was used to remove any tilts in the brain due to the patient's between scans movement inside the scanner. Then, both images were smoothed with a 6 mm full width at half maximum (FWHM) Gaussian filter, and magnetization transfer ratio (MTR) for each voxel was calculated using the following formula:

$$\text{MTR} = \frac{S_o - S_{\text{sat}}}{S_o}$$

where S_o is the signal intensity without saturation pulse (T1-weighted signal) and S_{sat} is signal with saturation pulse (T1 plus MT).

Next, SPGR images were segmented into three tissue classes (white, gray matter, and CSF) using an expected maximization segmentation algorithm (Wells et al., 1996), and white matter masks were additionally manually edited to remove any signal misclassified as white matter. In the next step, the same mutual registration information algorithms were used to co-register T1 with and without MT pulse and SPGR-based white matter masks to the DTI images. In addition, final registration output was manually checked by a trained radiologist (MK), and in case of even slight misregistration, the registration procedure was repeated, using exactly the same methods and parameters, except this time, an additional step was used that manually rotated the object images to match as closely as possible the target image orientation prior to using the mutual information registration algorithm.

All of these steps provided assurance that the images in all modalities, for all subjects, were in the same orientation. The study uses a nonlinear elastic warping technique that utilizes the

Daemon algorithm. This warping technique has been successfully used in diffusion studies (Guimond et al., 2001; Park et al., 2003, 2004). This normalization technique, although significantly more time-consuming and computationally demanding than the popular intensity-based approach, co-registers white matter images with the study-specific template with great accuracy, thus allowing us to look at each corresponding voxel across all subjects. The normalization study, published in *Neuroimage*, was carried out in order to verify the robustness of the registration algorithm. The method demonstrated lower registration error than traditional intensity-based registration algorithms (Park et al., 2003). The same method of co-registration, along with the same statistical comparison methods that we use here, have also been used in a voxel-based investigation of white matter fiber tract asymmetry abnormalities in schizophrenia (Park et al., 2004).

Object images for the registration included all of the diffusion images, and the parameters for the registration were derived from the registration, where T2W images (acquired as the part of the DTI procedure), FA images, and all 6 directional diffusion maps were used as multiple channels of the independent information. The target image for the normalization step was a study-specific template created by combining the averaged tensor field of all the normalized diffusion images and the averaged deformation field (for details, see Park et al., 2004). The co-registration parameters (i.e., the function describing displacement of each voxel of the object image to match the location of the corresponding voxel in the target image, which was derived from multi-channel registration of diffusion data) were then applied to the remaining modalities (white matter SPGR derived masks, T1W with and without MT), and the white matter masks were applied in order to extract only voxels belonging to the white matter in the further statistical analysis.

One-way between-group ANOVAs were then applied to the data sets on a voxel-by-voxel basis. Clusters were reported as significantly different between groups if they survived the 0.005 threshold, with clusters smaller than 50 voxels being excluded from the results map. This statistical analysis was performed for both FA and MTR maps of voxels belonging to white matter only. Results of both the FA as well as the MTR analyses were superimposed onto the averaged FA map, where fiber tracts demonstrating group differences have been located (for an example of a single slice showing the anatomical locations of major fiber tracts, see Fig. 1).

Demographic variables were also examined with between-group *t* tests.

In addition, to investigate further the relationship between FA and MTR values, mean FA and MTR values for each subject were extracted for each cluster that showed FA group abnormalities, and Spearman rank order correlations between FA and MTR were calculated for each region separately for controls and for schizophrenic subjects.

Finally, the relationships between FA, MTR age, and medication (all patients were receiving antipsychotic medication when the MR scan was acquired and the medication dosages were converted to chlorpromazine equivalents) were also investigated. Furthermore, to confirm findings from our previous report of cingulum bundle integrity relationship to the neuropsychological tests of executive function (Kubicki et al., 2003; Nestor et al., 2004), subjects from both groups were evaluated using the Wisconsin Card Sorting Test (WCST).

Results

Subjects did not differ in age, PSES, gender, or handedness. Statistical maps of the voxel-by-voxel comparison in FA and MTR between schizophrenics and controls are shown in Figs. 2–5. Figures demonstrate voxels where intensity values (either FA Figs. 2 and 3 or MTR Figs. 4 and 5) were lower for schizophrenics than for controls. The opposite contrast, i.e., schizophrenics greater than controls, did not show any significant differences.

Lower diffusion anisotropy was observed in the schizophrenia group compared to controls for the anterior and middle (parietal) portions of the cingulum bundle bilaterally, bilaterally in the anterior and posterior portions of the superior occipito-frontal fasciculus, bilaterally in the internal capsule, the fornix, the corpus callosum, the right inferior occipito-frontal fasciculus, and the left arcuate fasciculus (Figs. 2 and 3).

MTR maps demonstrated changes in corpus callosum, fornix, right internal capsule, and anterior parts of the superior occipito-frontal fasciculus bilaterally, but not in the cingulate fasciculus, left internal capsule, arcuate fasciculus, or right inferior occipito-frontal fasciculus. In addition, right posterior cingulum bundle white matter showed MTR, but not FA changes in schizophrenia (Figs. 4 and 5).

Mean values of the FA and MTR for regions showing group differences are also displayed in Table 1.

Correlational analyses showed the highest relationship between FA and MTR, regardless of group, in the left cingulum bundle ($\rho = 0.73$, $df = 46$, $P < 0.0001$), the corpus callosum ($\rho = 0.62$, $df = 46$, $P < 0.0001$), and the fornix ($\rho = 0.79$, $df = 46$, $P < 0.0001$). Other regions that showed FA and MTR group differences also demonstrated moderate correlations between FA and MTR (the right internal capsule ($\rho = 0.53$, $df = 46$, $P < 0.0001$), left ($\rho = 0.45$, $df = 46$, $P = 0.001$) and right ($\rho = 0.53$, $df = 46$, $P < 0.0001$) superior longitudinal fasciculus) (see Table 2). In contrast, besides the left cingulum bundle, other areas that showed FA, but not MTR abnormalities in schizophrenia, did not show significant correlations between MTR and FA values in either group (see Table 2).

Neither age nor medication correlated with any of our measures. With respect to the neuropsychological tests, similar to the findings from our prior CB ROI study (Nestor et al., 2004), we found correlations between left CB integrity and WCST total incorrect ($\rho = -.471$, $df = 20$, $P = 0.042$), perseverative responses ($\rho = -.478$, $df = 20$, $P = 0.038$), and perseverative errors ($\rho = -.517$, $df = 20$, $P = 0.023$).

Discussion

Our results demonstrate that patients diagnosed with schizophrenia are characterized by decreased diffusion anisotropy within several fiber tracts, including the cingulum bundle, corpus callosum, internal capsule, fornix, inferior occipito-frontal fasciculi, superior occipito-frontal fasciculi, and arcuate fasciculus. In addition, patients with schizophrenia are characterized by decreased MTR within the internal posterior cingulum bundle, corpus callosum, internal capsule, fornix, and superior occipito-frontal fasciculus but not in other areas of white matter. These latter findings suggest that MTR provides important new information about white matter abnormalities in schizophrenia that is not gleaned from DTI findings alone.

More specifically, with respect to DTI findings (see Fig. 2), FA abnormalities within the CB are consistent with findings of other DTI investigations (Kubicki et al., 2003; Sun et al., 2003; Wang et al., 2004). In addition, histological (Benes et al., 1986, 2001; Bouras et al., 2001), as well as functional studies (Carter et al., 1997, 2001; Cohen et al., 1998; Nordahl et al., 2001), point to inefficient communication between frontal and temporal lobe regions, subserved by the CB. We note also that our current study replicates our previous findings from an ROI DTI analysis of cingulum bundle (Kubicki et al., 2003). Our findings of CC anisotropy abnormalities are also consistent with other findings in the literature (Agartz et al., 2001; Foong et al., 2001; Ardekani et al., 2003). Moreover, Gruzelier (1999) speculates that information processing deficits in schizophrenia are related to defective interhemispheric communication, mediated by the CC. Another speculation is that, because of the long maturation period for CC myelination, an insult to the developing brain may contribute to a decrease in connectivity

between the right and left hemispheres (Njokiktjen, 1988) and thus might explain the lack of asymmetry between the hemispheres observed in schizophrenia.

The internal capsule findings reported in this study are consistent with Buchsbaum et al. (1998), who reported diffusion anisotropy abnormalities in the internal capsule in schizophrenia. The thalamo-cortical projection through the anterior limb of the internal capsule is the final pathway for all higher cognitive feedback loops connecting the frontal lobe and the basal ganglia (Nolte, 1999). Thus, damage to the internal capsule fiber tracts could lead to a “functional disconnection” of the feedback loops, resulting in behavioral and intellectual symptoms observed in patients with schizophrenia. The fornix has not previously been investigated in DTI studies of schizophrenia; however, our FA findings are consistent with MRI structural abnormalities observed in hippocampus (see review in Shenton et al., 2001). As the fornix is a major pathway providing connections between the hippocampus and other brain regions such as septal nuclei, nucleus accumbens, and the mammillary bodies, abnormalities here likely affect spatial learning and different aspects of memory.

Inferior occipito-frontal fasciculus and uncinate fasciculus abnormalities reported in this study are important as these fasciculi form the temporal stem, a brain region reported to be abnormal in schizophrenia (Burns et al., 2003; Kubicki et al., 2002b). Moreover, the UF is the largest white matter connection between the frontal and temporal lobes, and it also connects the amygdala and the uncus with the subcallosal region (Ebeling and von Cramon, 1992; Kier et al., 2004; Klingler and Gloor, 1960). This brain region may therefore play an important role in a variety of functions, including emotions and episodic memory, and its pathology may play an important role in the neuropathology of schizophrenia. Superior occipito-frontal fasciculus abnormalities reported in our study have not previously been reported in schizophrenia. Of note, the anterior portion is situated within the prefrontal white matter, which has been shown to have lower FA in several DTI studies in schizophrenia (Buchsbaum et al., 1998; Lim et al., 1999; Minami et al., 2003). Furthermore, as noted above, prefrontal white matter is a brain region that has been investigated in the histopathologic studies where abnormalities in oligodendrocyte function have been reported (Uranova et al., 2001, 2004).

Finally, our arcuate fasciculus findings suggest a disruption in connections between the posterior temporal/inferior parietal region—(on the left, Wernicke's area), including the angular gyrus and the posterior portion of superior temporal gyrus with the inferior prefrontal region (on the left, Broca's area; Felleman and Van Essen, 1991; Petrides and Pandya, 1988), which likely plays a major role in language processes, and likely in abnormalities in these processes in schizophrenia. Of note here, previous DTI studies have reported arcuate fasciculus abnormalities in schizophrenia (Burns et al., 2003), as well as an association between arcuate fasciculus abnormalities and hallucinations (Hubl et al., 2004).

We note that the daemon algorithm, in combination with LSDI, allowed us to precisely localize diffusion abnormalities within fiber tracts in patients with schizophrenia (for anatomical reference, see Fig. 1). In addition, our findings are consistent with findings of other DTI schizophrenia studies. Nonetheless, the specificity of these findings only became clearer with the addition of MTR. This is the case because, as mentioned previously, changes in diffusion anisotropy can be attributed to multiple etiologies, including alterations in the number and density of axons, alterations in their thickness, and alterations in the thickness of the myelin sheaths surrounding axons, as well as to alterations in the organization/direction of fibers within the fiber bundles.

Thus, while other studies have evaluated MTR in schizophrenia (e.g., Bagary et al., 2002, 2003; Foong et al., 2000, 2001), our study is the first to combine both DTI and MTR in the same subjects. This combination led to more specific findings with respect to white matter

abnormalities in schizophrenia. Our results demonstrate, for example, that some white matter abnormalities observed in DTI in schizophrenia are also present on MTR maps (see Fig. 4). This most likely indicates the presence of myelin integrity abnormalities within some of the fiber bundles, particularly fronto-occipital or fronto-thalamic connections subserved by the superior longitudinal fasciculus, and the anterior limb of the internal capsule, as well as midline structures, such as the fornix and the corpus callosum. On the other hand, tracts such as the anterior and middle portions of the cingulum bundle, the uncinate and arcuate fasciculi, did not show MTR abnormalities, indicating that changes in the diffusion signal are most likely due to a group difference in the organization or coherence of the fibers within these fiber bundles and not due to the myelin abnormalities. In addition, the posterior portion of the right cingulum bundle, localized within the medial temporal region, demonstrated MTR, but not FA abnormalities in schizophrenia compared to control subjects, suggesting the higher sensitivity of the MTR measurements in this region (possibly due to the susceptibility artifacts commonly present in this region on diffusion images).

Thus, the fact that some white matter bundles show FA abnormalities, with no MTR changes, while other white matter bundles show MTR changes without DTI abnormalities is both interesting and requires further evaluation. We believe that such findings suggest that MTR is not merely one more DTI-like technique with weaker sensitivity than the DTI, but it instead reflects different findings that further suggest the importance of combining both DTI and MTR in order to increase the specificity of the white matter findings in schizophrenia. Of further note, we believe that our findings also indicate that myelin/axonal abnormalities, detected in genetic as well as histopathological studies in schizophrenia, are, in fact, not as widely distributed as would be suggested by DTI studies but may instead be limited to a small number of fiber bundles interconnecting prefrontal cortex. Sub-grouping patients with such anomalies may therefore be a key factor in genetic studies of schizophrenia where individuals with a heavier genetic loading may have more myelin-related abnormalities in a smaller set of fiber tracts in the brain. This speculation warrants further investigation.

Support for the latter speculation comes from correlational analyses, which detected a strong relationship between FA and MTR measurements in areas that showed FA group differences but no relationship between these values in regions that showed FA but no MTR abnormalities in schizophrenia (see Table 2). The only exception was the CB, where FA decrease was observed in the anterior and middle portion of the bundle, without MTR changes, even though these two values were strongly correlated on the left side. Moreover, MTR changes showed decreased values in the posterior-temporal part of this bundle, without FA abnormalities. These complicated relationships, especially the discrepancy between the correlational analysis, which showed a high correlation between FA and MTR in the cingulum bundle, and the MTR analysis, which did not show any group differences in this region, are most likely due to the statistical threshold possibly being set too high for the MTR analysis. Thus, our results, even though clearly demonstrating CB integrity abnormalities in schizophrenia, need to be further investigated using tracking methods that allow for whole bundle measurements and likely increase the accuracy and sensitivity of both FA and MTR measurements.

With respect to limitations of the study, we note that, even though our multi-channel tensorial co-registration procedure is much more precise than the more popular co-registration based on T1 or FA signal intensity, the algorithm still does not perform well when anatomical variability across subjects is present, for example, when there are two instead of one branch of a smaller bundle. This approach is thus more reliable for large fiber tracts and less precise for the secondary or tertiary bundles observed only in a fraction of a healthy population. We also note that the spatial resolution of our scans was relatively low, and thus partial volume effects might play a role in data analysis and co-registration. We note also that the sample size, although comparable with most DTI studies to date, was relatively small. In addition, it is possible that,

due to the lower sensitivity of MTR (we used T1W MT images, while the strongest MT effect has been described when proton density images are used), we might not have been able to detect myelin differences that existed in the data. It is also unclear how specific MTR is to the myelin changes. In general, much larger MTR effects are observed in white matter than in gray matter, and most of the studies conducted so far have excluded MT effects of less than 10% (observed in gray matter), which were attributed to noise. This, as well as the fact that we were interested in white matter fiber tracts, was the reason for including in our statistical comparison only white matter brain regions. On the other hand, a recent MTR/DTI study in post-mortem tissue demonstrated correlations between MTR values and axonal density (Pfefferbaum and Sullivan, 2003), suggesting that the small MTR effects observed within the gray matter and group differences detected in previous MTR schizophrenia studies are valid. Additionally, while it is possible that the threshold we used for FA analysis is too stringent for MTR data, we believe that the cluster level statistic we used is a valid approach, particularly given the normal data distribution and the fact that the white matter voxels form continuous structures—fiber tracts.

In summary, this is the first schizophrenia voxel-based study that takes advantage of multidirectional tensor information for the co-registration of white matter fiber bundles from several individuals to a study-specific template. It is also the first study to combine DTI FA and MTR methods to investigate white matter abnormalities in schizophrenia, as well as among the first to investigate MTR white matter abnormalities in schizophrenia. Our findings, cautiously interpreted, demonstrate the advantage of using a more precise registration technique, in combination with two methods (DTI/FA and MTR), to aid in the specificity of defining more precisely the pathological processes taking place in white matter fiber tracts in schizophrenia.

Acknowledgments

The authors would like to thank Marie Fairbanks for her administrative assistance. Additionally, we gratefully acknowledge the support of the National Alliance for Research on Schizophrenia and Depression (MK), The Wodcroft Foundation (MK), the National Institute of Health (R03 MH 068464-02 to MK, R01 NS 39335 to RM and SEM, NIH P41 RR 13218 to RK, R01 MH 40799 to RWM, and K02 MH 01110 and R01 MH 50747 to MES), the Department of Veterans Affairs Merit and REAP Awards (PGN, MN, MES, RWM), a VA Psychiatry/Neuroscience Research Fellowship Award (MF).

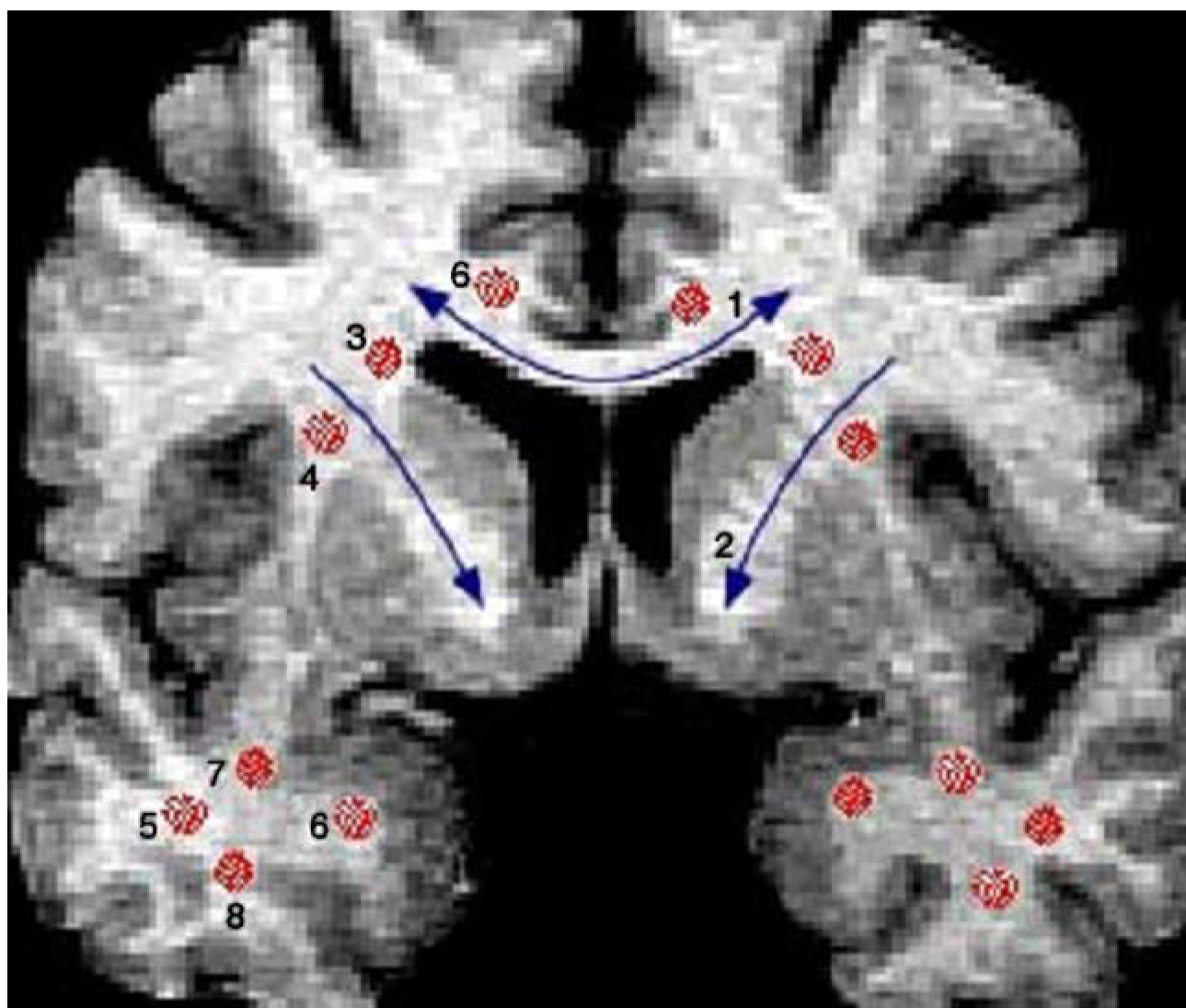
References

- Agartz I, Andersson JL, Skare S. Abnormal brain white matter in schizophrenia: a diffusion tensor imaging study. *NeuroReport* 2001;12:2251–2254. [PubMed: 11447344]
- Ardekani BA, Nierenberg J, Hoptman MJ, Javitt DC, Lim KO. MRI study of white matter diffusion anisotropy in schizophrenia. *NeuroReport* 2003;14:2025–2029. [PubMed: 14600491]
- Ashburner J, Friston KJ. Voxel-based morphometry—the methods. *NeuroImage* 2000;11:805–821. [PubMed: 10860804]
- Bagary MS, Foong J, Maier M, et al. A magnetization transfer analysis of the thalamus in schizophrenia. *J. Neuropsychiatry Clin. Neurosci* 2002;14:443–448. [PubMed: 12426413]
- Bagary MS, Symms MR, Barker GJ, Mutsatsa SH, Joyce EM, Ron MA. Gray and white matter brain abnormalities in first-episode schizophrenia inferred from magnetization transfer imaging. *Arch. Gen. Psychiatry* 2003;60:779–788. [PubMed: 12912761]
- Beaulieu C, Allen P. Determinants of anisotropic water diffusion in nerves. *Med. Risk Manag* 1994;3:394–400.
- Benes FM, Davidson J, Bird ED. Quantitative cytoarchitectural studies of the cerebral cortex of schizophrenics. *Arch. Gen. Psychiatry* 1986;43:31–35. [PubMed: 3942472]

- Benes FM, Vincent SL, Todtenkopf M. The density of pyramidal and nonpyramidal neurons in anterior cingulate cortex of schizophrenic and bipolar subjects. *Biol. Psychiatry* 2001;50:395–406. [PubMed: 11566156]
- Bouras C, Kovari E, Hof PR, Riederer BM, Giannakopoulos P. Anterior cingulate cortex pathology in schizophrenia and bipolar disorder. *Acta Neuropathol. (Berl.)* 2001;102:373–379. [PubMed: 11603813]
- Buchsbaum MS, Tang CY, Peled S, et al. MRI white matter diffusion anisotropy and PET metabolic rate in schizophrenia. *Neuro-Report* 1998;9:425–430.
- Burns J, Job D, Bastin ME, et al. Structural disconnectivity in schizophrenia: a diffusion tensor magnetic resonance imaging study. *Br. J. Psychiatry* 2003;182:439–443. [PubMed: 12724248]
- Carter CS, Mintun M, Nichols T, Cohen JD. Anterior cingulate gyrus dysfunction and selective attention deficits in schizophrenia: [15O]H₂O PET study during single-trial Stroop task performance. *Am. J. Psychiatry* 1997;154:1670–1675. [PubMed: 9396944]
- Carter CS, MacDonald AW III, Ross LL, Stenger VA. Anterior cingulate cortex activity and impaired self-monitoring of performance in patients with schizophrenia: an event-related fMRI study. *Am. J. Psychiatry* 2001;158:1423–1428. [PubMed: 11532726]
- Cohen RM, Nordahl TE, Semple WE, Andreason P, Pickar D. Abnormalities in the distributed network of sustained attention predict neuroleptic treatment response in schizophrenia. *Neuropsychopharmacology* 1998;19:36–47. [PubMed: 9608575]
- Cotter DR, Pariante CM, Everall IP. Glial cell abnormalities in major psychiatric disorders: the evidence and implications. *Brain Res. Bull* 2001;55:585–595. [PubMed: 11576755]
- Coyle JT, Tsai G, Goff DC. Ionotropic glutamate receptors as therapeutic targets in schizophrenia. *Curr. Drug Targets. CNS Neurol. Disord* 2002;1:183–189. [PubMed: 12769626]
- Ebeling U, von Cramon D. Topography of the uncinate fascicle and adjacent temporal fiber tracts. *Acta Neurochir. (Wien)* 1992;115:143–148. [PubMed: 1605083]
- Felleman DJ, Van Essen DC. Distributed hierarchical processing in the primate cerebral cortex. *Cereb. Cortex* 1991;1:1–47. [PubMed: 1822724]
- Foong J, Maier M, Barker GJ, Brocklehurst S, Miller DH, Ron MA. In vivo investigation of white matter pathology in schizophrenia with magnetisation transfer imaging. *J. Neurol., Neurosurg. Psychiatry* 2000;68:70–74. [PubMed: 10601405]
- Foong J, Symms MR, Barker GJ, et al. Neuropathological abnormalities in schizophrenia: evidence from magnetization transfer imaging. *Brain* 2001;124:882–892. [PubMed: 11335691]
- Foong J, Symms MR, Barker GJ, Maier M, Miller DH, Ron MA. Investigating regional white matter in schizophrenia using diffusion tensor imaging. *NeuroReport* 2002;13:333–336. [PubMed: 11930133]
- Friston KJ, Frith CD. Schizophrenia: a disconnection syndrome? *Clin. Neurosci* 1995;3:89–97. [PubMed: 7583624]
- Ge Y, Grossman RI, Udupa JK, Babb JS, Mannon LJ, McGowan JC. Magnetization transfer ratio histogram analysis of normal-appearing gray matter and normal-appearing white matter in multiple sclerosis. *J. Comput. Assist. Tomogr* 2002;26:62–68. [PubMed: 11801905]
- Good CD, Johnsrude I, Ashburner J, Henson RN, Friston KJ, Frackowiak RS. Cerebral asymmetry and the effects of sex and handedness on brain structure: a voxel-based morphometric analysis of 465 normal adult human brains. *NeuroImage* 2001;14:685–700. [PubMed: 11506541]
- Grossman RI, Gomori JM, Ramer KN, Lexa FJ, Schnall MD. Magnetization transfer: theory and clinical applications in neuroradiology. *Radiographics* 1994;14:279–290. [PubMed: 8190954]
- Gruzelier JH. Functional neuropsychophysiological asymmetry in schizophrenia: a review and reorientation. *Schizophr. Bull* 1999;25:91–120. [PubMed: 10098916]
- Gudbjartsson H, Maier SE, Mulkern RV, Morocz IA, Patz S, Jolesz FA. Line scan diffusion imaging. *Magn. Reson. Med* 1996;36:509–519. [PubMed: 8892201]
- Guimond A, Roche A, Ayache N, Meunier J. Three-dimensional multimodal brain warping using the demons algorithm and adaptive intensity corrections. *IEEE Trans. Med. Imaging* 2001;20:58–69. [PubMed: 11293692]
- Guimond, A.; Gutmman, CRG.; Warfield, SK.; Westin, C-F. Deformable registration of DT-MRI data based on transformation invariant tensor characteristics.. *Proceedings of the IEEE International*

- Symposium on Biomedical Imaging (ISBI'02); Washington, DC, USA. July 7–10, 2002; 2002. p. 761–764.
- Hakak Y, Walker JR, Li C, et al. Genome-wide expression analysis reveals dysregulation of myelination-related genes in chronic schizophrenia. *Proc. Natl. Acad. Sci. U. S. A* 2001;98:4746–4751. [PubMed: 11296301]
- Harrison PJ. The neuropathology of schizophrenia. A critical review of the data and their interpretation. *Brain* 1999;122(Pt 4):593–624. [PubMed: 10219775]
- Harrison PJ, Owen MJ. Genes for schizophrenia? Recent findings and their pathophysiological implications. *Lancet* 2003;361:417–419. [PubMed: 12573388]
- Hubl D, Koenig T, Strik W, et al. Pathways that make voices: white matter changes in auditory hallucinations. *Arch. Gen. Psychiatry* 2004;61:658–668. [PubMed: 15237078]
- Huppi PS, Maier SE, Peled S, et al. Microstructural development of human newborn cerebral white matter assessed in vivo by diffusion tensor magnetic resonance imaging. *Pediatr. Res* 1998;44:584–590. [PubMed: 9773850]
- Hyde TM, Ziegler JC, Weinberger DR. Psychiatric disturbances in metachromatic leukodystrophy. Insights into the neurobiology of psychosis. *Arch. Neurol* 1992;49:401–406. [PubMed: 1532712]
- Kier EL, Staib LH, Davis LM, Bronen RA. MR imaging of the temporal stem: anatomic dissection tractography of the uncinate fasciculus, inferior occipitofrontal fasciculus, and Meyer's loop of the optic radiation. *Am. J. Neuroradiol* 2004;25:677–691. [PubMed: 15140705]
- Klingler J, Gloor P. The connections of the amygdala and of the anterior temporal cortex in the human brain. *J. Comp. Neurol* 1960;115:333–369. [PubMed: 13756891]
- Kraepelin, E. *Dementia Praecox*. Churchill Livingstone Inc.; New York: 1919/1971.
- Kubicki M, Westin CF, Maier SE, et al. Diffusion tensor imaging and its application to neuropsychiatric disorders. *Harv. Rev. Psychiatry* 2002a;10:324–336. [PubMed: 12485979]
- Kubicki M, Westin CF, Maier SE, et al. Uncinate fasciculus findings in schizophrenia: a magnetic resonance diffusion tensor imaging study. *Am. J. Psychiatry* 2002b;159:813–820. [PubMed: 11986136]
- Kubicki M, Westin CF, Nestor PG, et al. Cingulate fasciculus integrity disruption in schizophrenia: a magnetic resonance diffusion tensor imaging study. *Biol. Psychiatry* 2003;54:1171–1180. [PubMed: 14643084]
- Kubicki M, Maier SE, Westin CF, et al. Comparison of single-shot echo-planar and line scan protocols for diffusion tensor imaging. *Acad. Radiol* 2004;11:224–232. [PubMed: 14974598]
- Lim KO, Helpert JA. Neuropsychiatric applications of DTI—a review. *NMR Biomed* 2002;15:587–593. [PubMed: 12489105]
- Lim KO, Hedehus M, Moseley M, de Crespigny A, Sullivan EV, Pfefferbaum A. Compromised white matter tract integrity in schizophrenia inferred from diffusion tensor imaging. *Arch. Gen. Psychiatry* 1999;56:367–374. [PubMed: 10197834]
- Maier SE, Gudbjartsson H, Patz S, et al. Line scan diffusion imaging: characterization in healthy subjects and stroke patients. *Am. J. Roentgenol* 1998;171:85–93. [PubMed: 9648769]
- McGuire PK, Frith CD. Disordered functional connectivity in schizophrenia [editorial]. *Psychol. Med* 1996;26:663–667. [PubMed: 8817700]
- Minami T, Nobuhara K, Okugawa G, et al. Diffusion tensor magnetic resonance imaging of disruption of regional white matter in schizophrenia. *Neuropsychobiology* 2003;47:141–145. [PubMed: 12759557]
- Nestor P, Kubicki M, McCarley R, et al. Neuropsychology of learning and memory and MRI diffusion tensor correlates in schizophrenia. *Neuropsychopharmacology* 2004;18(4):629–637.
- Njiokiktjien, C. *Pediatric Behavioural Neurology*. Suyi Publicaties; Amsterdam: 1988.
- Nolte, J. *The Human Brain: An Introduction To Its Functional Anatomy*. Mosby Inc.; St. Louis: 1999.
- Nordahl TE, Carter CS, Salo RE, et al. Anterior cingulate metabolism correlates with Stroop errors in paranoid schizophrenia patients. *Neuropsychopharmacology* 2001;25:139–148. [PubMed: 11377927]
- Park HJ, Kubicki M, Shenton ME, et al. Spatial normalization of diffusion tensor MRI using multiple channels. *NeuroImage* 2003;20:1995–2009. [PubMed: 14683705]

- Park HJ, Westin CF, Kubicki M, et al. White matter hemisphere asymmetries in healthy subjects and in schizophrenia: a diffusion tensor MRI study. *NeuroImage* 2004;24:213–223. [PubMed: 15325368]
- Petrides M, Pandya DN. Association fiber pathways to the frontal cortex from the superior temporal region in the rhesus monkey. *J. Comp. Neurol* 1988;273:52–66. [PubMed: 2463275]
- Pfefferbaum A, Sullivan EV. Increased brain white matter diffusivity in normal adult aging: relationship to anisotropy and partial voluming. *Magn. Reson. Med* 2003;49:953–961. [PubMed: 12704779]
- Rovaris M, Filippi M, Minicucci L, et al. Cortical/subcortical disease burden and cognitive impairment in patients with multiple sclerosis. *Am. J. Neuroradiol* 2000;21:402–408. [PubMed: 10696031]
- Rugg-Gunn FJ, Eriksson SH, Symms MR, Barker GJ, Duncan JS. Diffusion tensor imaging of cryptogenic and acquired partial epilepsies. *Brain* 2001;124:627–636. [PubMed: 11222461]
- Shenton ME, Dickey CC, Frumin M, McCarley RW. A review of MRI findings in schizophrenia. *Schizophr. Res* 2001;49:1–52. [PubMed: 11343862]
- Sun Z, Wang F, Cui L, et al. Abnormal anterior cingulum in patients with schizophrenia: a diffusion tensor imaging study. *Neuro-Report* 2003;14:1833–1836.
- Tamminga CA. Schizophrenia and glutamatergic transmission. *Crit. Rev. Neurobiol* 1998;12:21–36. [PubMed: 9444480]
- Uranova N, Orlovskaya D, Vikhrev O, et al. Electron microscopy of oligodendroglia in severe mental illness. *Brain Res. Bull* 2001;55:597–610. [PubMed: 11576756]
- Uranova NA, Vostrikov VM, Orlovskaya DD, Rachmanova VI. Oligodendroglial density in the prefrontal cortex in schizophrenia and mood disorders: a study from the Stanley neuropathology consortium. *Schizophr. Res* 2004;67:269–275. [PubMed: 14984887]
- Wang F, Sun Z, Cui L, et al. Anterior cingulum abnormalities in male patients with schizophrenia determined through diffusion tensor imaging. *Am. J. Psychiatry* 2004;161:573–575. [PubMed: 14992988]
- Watkins KE, Paus T, Lerch JP, et al. Structural asymmetries in the human brain: a voxel-based statistical analysis of 142 MRI scans. *Cereb. Cortex* 2001;11:868–877. [PubMed: 11532891]
- Weinberger DR. Implications of normal brain development for the pathogenesis of schizophrenia. *Arch. Gen. Psychiatry* 1987;44:660–669. [PubMed: 3606332]
- Weinberger DR, Berman KF, Suddath R, Torrey EF. Evidence of dysfunction of a prefrontal-limbic network in schizophrenia: a magnetic resonance imaging and regional cerebral blood flow study of discordant monozygotic twins. *Am. J. Psychiatry* 1992;149:890–897. [PubMed: 1609867]
- Wells WM III, Viola P, Atsumi H, Nakajima S, Kikinis R. Multi-modal volume registration by maximization of mutual information. *Med. Image Anal* 1996;1:35–51. [PubMed: 9873920]
- Wernicke, C. *Grundrisse der Psychiatrie*. Thieme; Leipzig: 1906.



1. Corpus callosum, 2. Internal capsule, 3. Superior occipitofrontal fasciculus,
4. Superior longitudinal fasciculus, 5. Inferior occipitofrontal fasciculus,
6. Cingulum, 7. Uncinate, fasciculus, 8. Inferior longitudinal fasciculus

Fig. 1.
Schematic of anatomical locations of the white matter fiber tracts.

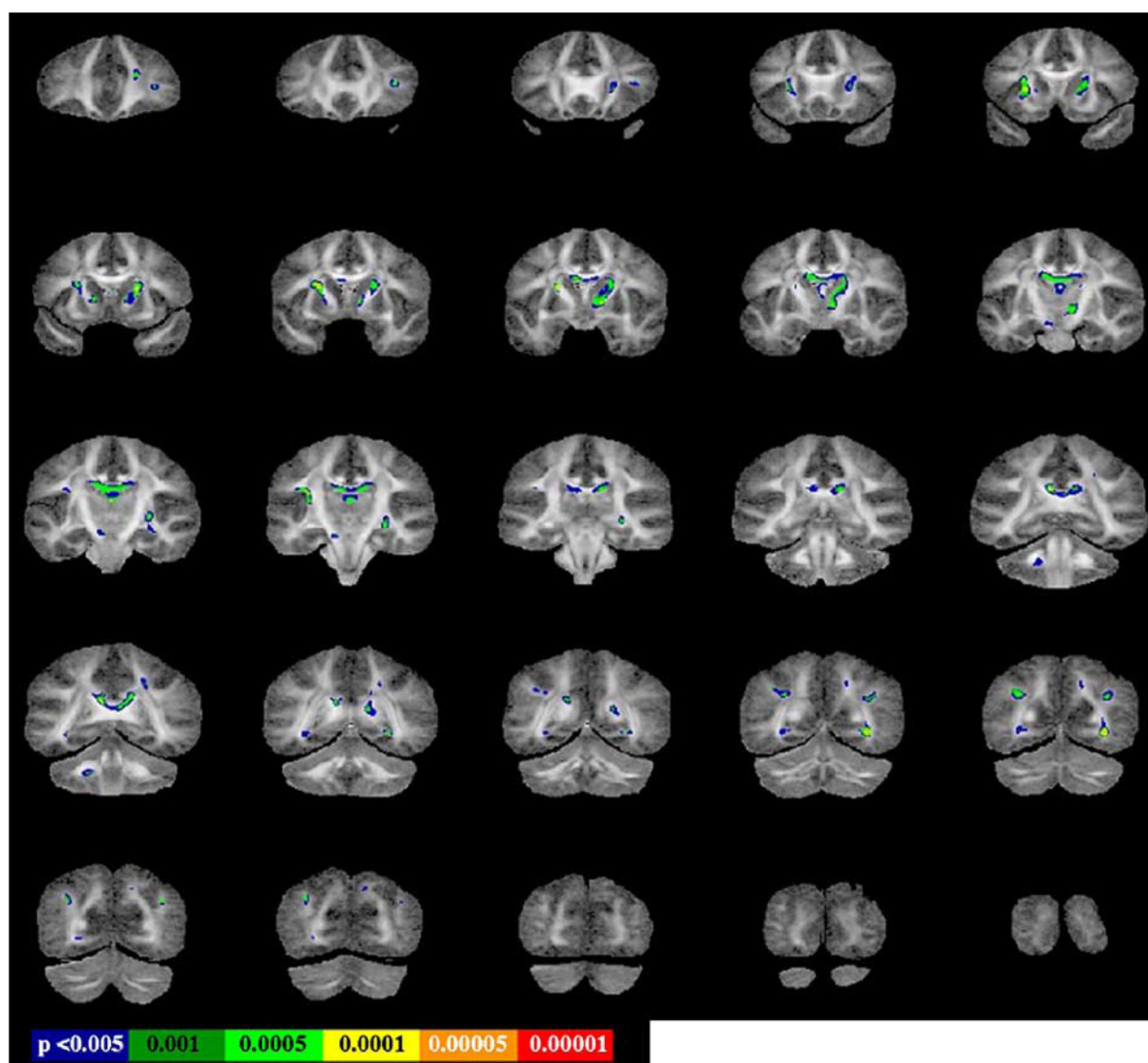


Fig. 2.

FA group differences superimposed on FA study specific template. Statistical threshold set to $P = 0.005$, with extent threshold 50 voxels.

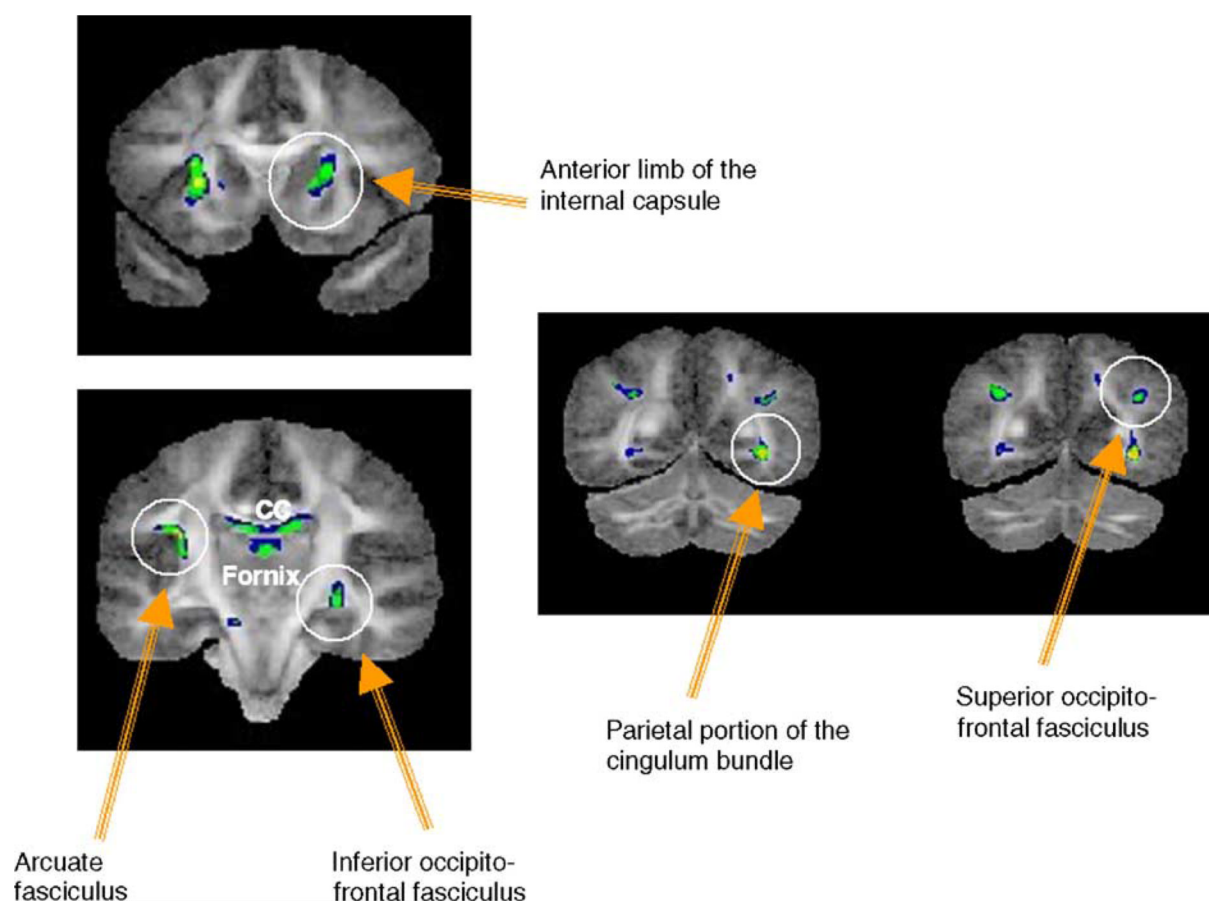


Fig. 3.
Specific locations of FA group differences.

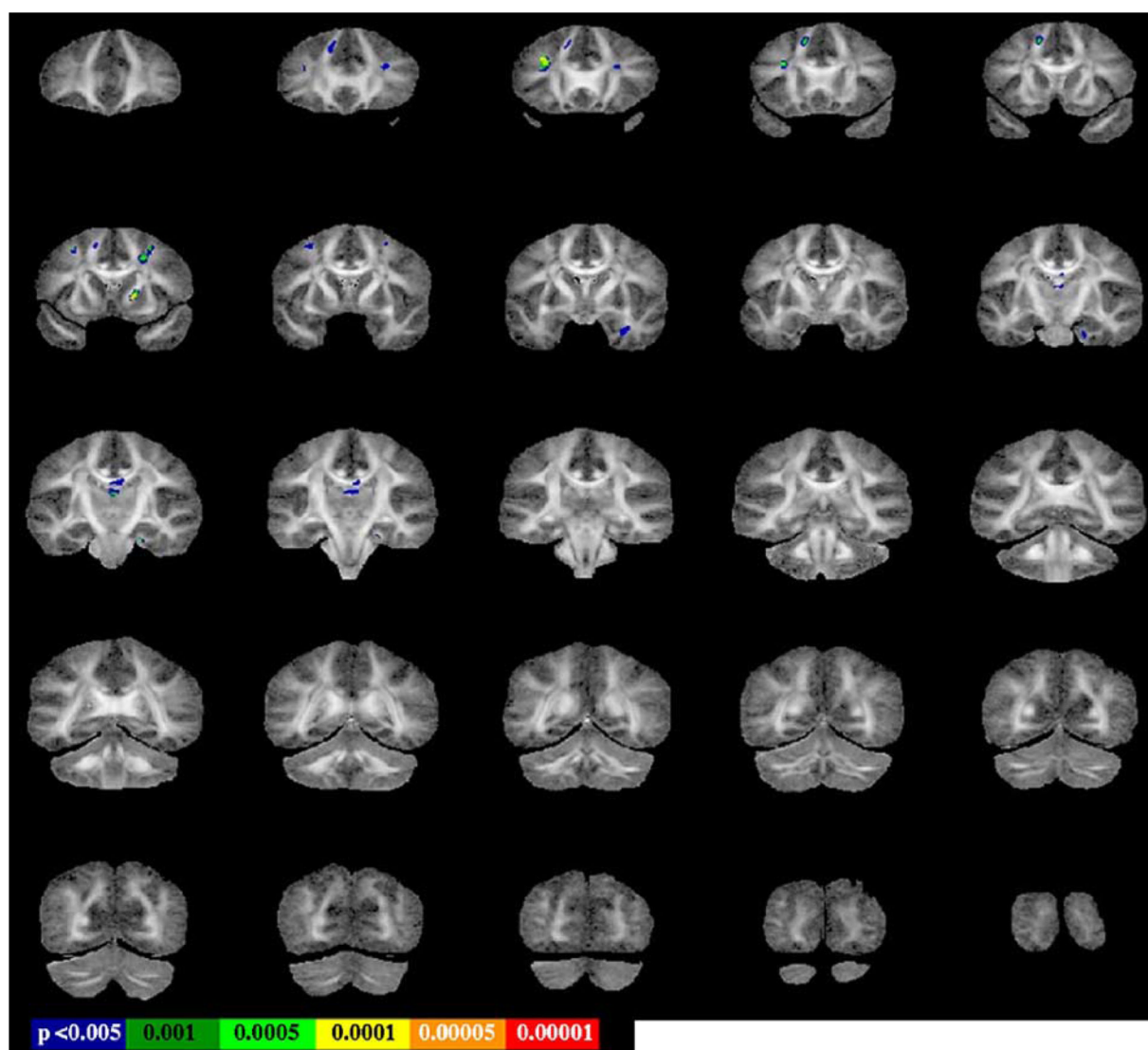


Fig. 4. MTR group differences superimposed on FA study-specific template. Statistical threshold set to $P = 0.005$, with extent threshold 50 voxels.

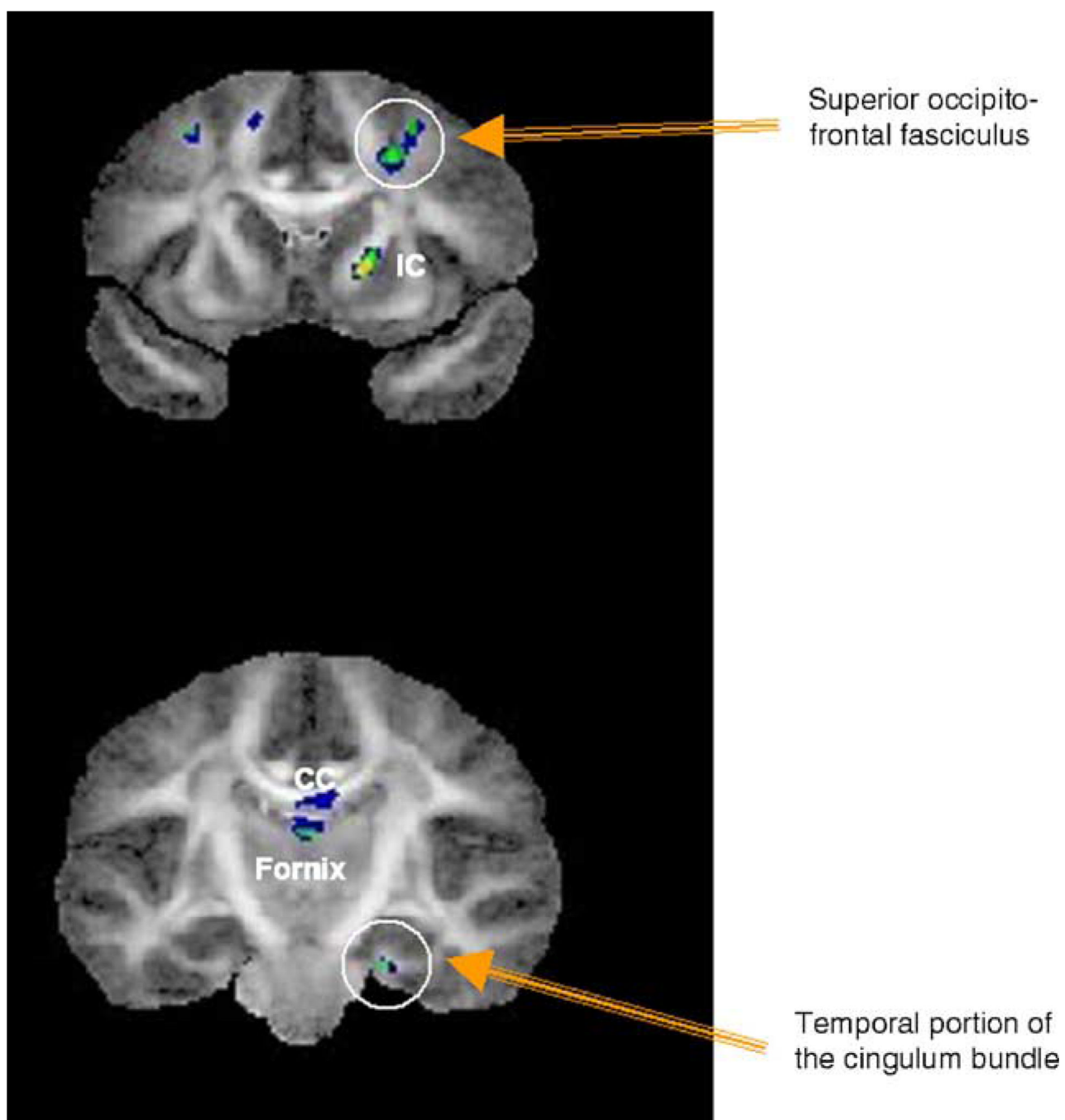


Fig. 5.
Specific locations of MTR group differences.

Table 1

Mean FA and mean MTR within the tracts demonstrating significant group differences

	Mean FA-NC	Mean FA-schizophrenics	P value (uncorrected)	Mean MTR (%) - NC	Mean MTR (%) -schizophrenics	P value (uncorrected)
Left cingulum bundle	0.47 (0.04)	0.40 (0.03)	0.0005	20.1 (2.8)	19.1 (4.1)NS	
Right cingulum bundle	0.44 (0.02)	0.41 (0.03)	0.0001	20.9 (2.6)	20.7 (2.6)NS	
Right inferior occipito-frontal fasciculus	0.45 (0.03)	0.39 (0.04)	0.000002	23.2 (2.2)	21.61 (2.5)NS	
Left internal capsule	0.41 (0.02)	0.38 (0.02)	0.00002	23.8 (2.9)	211.5 (3.5)NS	
Right internal capsule	0.43 (0.02)	0.38 (0.03)	0.00005	21.0 (2.7)	19.1 (3.2)0.000001	
Corpus callosum	0.49 (0.06)	0.41 (0.07)	0.00002	19.2 (3.1)	16.6 (4.1)0.000009	
Left arcuate fasciculus	0.45 (0.03)	0.41 (0.02)	0.00006	24.2 (2.7)	24.0 (3.5)NS	
Fornix	0.30 (0.08)	0.21 (0.09)	0.00005	15.2 (2.3)	12.9 (1.9)0.001	
Left superior longitudinal fasciculus	0.38 (0.04)	0.33 (0.04)	0.00009	20.5 (4.4)	17.2 (4.4)0.0004	
Right superior longitudinal fasciculus	0.40 (0.05)	0.34 (0.05)	0.0002	22.9 (4.7)	19.0 (4.9)0.001	

Table 2

Correlations between FA and MTR values

	Correlation coefficients (all)	Correlation coefficients (NC)	Correlation coefficients (SCHIZ)
Left cingulum bundle	0.73**	0.74**	0.68**
Right cingulum bundle	0.11	0.33	-0.28
Right inferior occipito-frontal fasciculus	0.40**	0.26	0.35
Left internal capsule	0.18	0.17	-0.23
Right internal capsule	0.53**	0.30	0.57**
Corpus callosum	0.62**	0.54**	0.62**
Left arcuate fasciculus	0.31*	-0.03	0.34
Fornix	0.79**	0.78**	0.73**
Left superior longitudinal fasciculus	0.45**	0.26	0.51*
Right superior longitudinal fasciculus	0.53**	0.40*	0.52*

* $P < 0.05$.** $P < 0.01$.