LETTER

Computer-Aided Diagnosis of Splenic Enlargement Using Wave Pattern of Spleen in Abdominal CT Images: Initial Observations

Won SEONG[†a)], ***Member***, **June-Sik CHO**[††], **Seung-Moo NOH**[†††], ***and*** **Jong-Won PARK**[†], ***Nonmembers***

SUMMARY In general, the spleen accompanied by abnormal abdomen is hypertrophied. However, if the spleen size is originally small, it is hard to detect the splenic enlargement due to abnormal abdomen by simply measure the size. On the contrary, the spleen size of a person having a normal abdomen may be large by nature. Therefore, measuring the size of spleen is not a reliable diagnostic measure of its enlargement or the abdomen abnormality. This paper proposes an automatic method to diagnose the splenic enlargement due to abnormality, by examining the boundary pattern of spleen in abdominal CT images.

key words: *computer-aided diagnosis, abdominal CT images, spleen, liver cirrhosis, wave pattern*

1. Introduction

Generally, it is known that the spleen accompanied by abnormal abdomen is hypertrophied [1]–[7]. However, in some cases, patients with abnormal abdomen don't show hypertrophy of the spleen [8]. On the contrary, even the size of the person's spleen with a normal abdomen may be large by nature and not abnormally hypertrophied. Therefore, measuring size of the spleen is not a reliable method, and thus it is difficult to make a correct diagnosis by only considering the spleen's size. For this reason, based on their own standards, radiologists make a final diagnosis of whether the spleen is normal or abnormal by examining the pattern and shape of the spleen and the size of the spleen at the same time.

It is known that the spleen accompanied by liver cirrhosis is hypertrophied or enlarged. We have examined a wave pattern at the left boundary of spleen on the abdominal CT images of patients with liver cirrhosis, and found that they are different from those on the images of a normal liver. It is noticed that the abdominal CT images of patient with liver cirrhosis shows strong bending in the wave pattern. In the case of normal liver, the images may also have a wave pattern, but its bends are not strong.

Therefore, the total waving area of the spleen with liver cirrhosis is found to be greater than that of the spleen with a normal liver. Moreover, we found that the waves of the spleen from the image with liver cirrhosis have the higher degree of circularity compared to the normal liver case. Based on the two observations above, we propose an automatic method to diagnose splenic enlargement by using the wave pattern of the spleen in abdominal CT images. The proposed automatic method improves the diagnostic performance compared with the conventional process based on the size of spleen.

Manuscript received May 26, 2009.
Manuscript revised July 9, 2009.

[†]The authors are with the Dept. of Information and Communication Engineering, Chungnam National University, 220 Goong-Dong, Yuseong-Gu, Daejeon 305–764 Korea.
[††]The author is with the Dept. of Diagnostic Radiology, Medical School, Chungnam National University, Korea.
[†††]The author is with the Dept. of General Surgery, Medical School, Chungnam National University, Korea.
a) E-mail: wseong@cnu.ac.kr

DOI: 10.1587/transinf.E92.D.2283

2. Methods

Figure 1 shows various CT images for abnormal and normal cases. By examining many cases, we found that the left boundary of the spleen, which is accompanied by liver cirrhosis is hypertrophied, has a distinctive wave pattern. Based on this observation, the automatic diagnostic procedure is proposed as shown in Fig. 2. In the figure, the first pre-processing step performs the image equalization and the background and muscle removal from abdominal CT images. Then, the spleen is segmented as shown in Fig. 3 and extracted as shown in Fig. 4. After the segmentation, the splenic enlargement is detected by using the following two measures, namely, the sum of wave areas and the degree of circularity.

2.1 Segmentation of the Spleen

Since the person's spleen with a abnormal abdomen does not have regular and narrowly ranged gray values, this study sets up a standard of the expected gray value of the spleen with the average of sample pixels in the ROI (Region of Interest) of the spleen as Fig. 3 (a). Center point M of ROI (40×40) is roughly selected as the center of the target spleen by the user. At this time, maximum value is taken by adding preselected gray value to the standard gray value and minimum value by subtracting preselected gray value from it. The standard range means the range between maximum value and minimum value. With the standard range, we measure the gray value of the pixels from M to 360 degree angle lines as Fig. 3 (b). If the gray value of pixels are in the standard range, we choose them as a part of the target spleen.

2.2 Sum of Wave Area

We represent this measure as the number of pixels, by extracting wave areas from the segmented spleen so that we may compare it for diagnosis with the threshold value

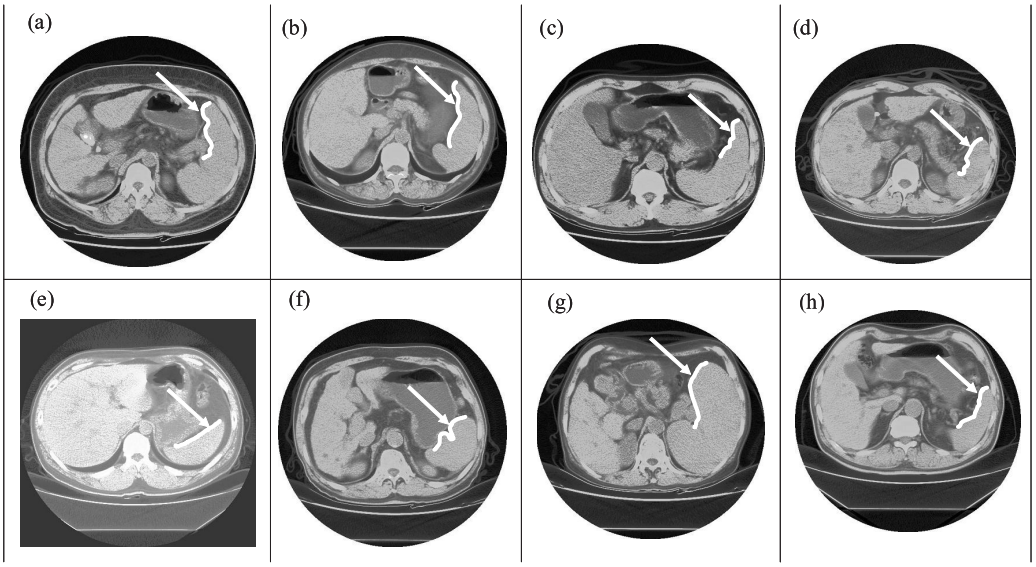

Fig. 1 Patterns of the left boundary of spleen for different cases. (a)–(d) Spleens having a wave pattern for the case of liver cirrhosis, (e) a spleen having no wave pattern for the case of normal liver, (f) a spleen having wave-like focal splenic enlargement for the case of liver cirrhosis, (g) a spleen having a wave pattern and hypertrophy for the case of liver cirrhosis, and (h) a spleen having a wave pattern for the case of normal liver.



Fig. 2 Schematic diagram of the proposed procedure. After the pre-processing and the segmentation, splenic enlargement is detected by using the wave area test and wave circularity test.

obtained in advance. To extract wave areas, we first draw a line from the top-middle point of the spleen, S, to vertex K of the first wave. Here, the wave vertex K can be obtained by determining the line which starts from point S and is tangential to the spleen boundary (see Fig. 5 (a)). Once vertex K of the first wave is determined as Fig. 5 (b), we can define and measure area A of the first wave. After getting area A, the area of the second wave, B, is to be calculated. To calculate this, we need to set vertex K of the first wave to the new starting point S of the second wave and repeat the procedure mentioned above. For next waves if any, this procedure is repeated.

2.3 Degree of Circularity

For an area obtained for the pervious measure, we may define the degree of circularity. Assuming a hypothetical circle which inscribes area A and has a diameter decided by straight line SK as shown in Fig. 6 (a), we define the degree of circularity of area A as the ratio of area A to a half of the circle area. For next areas, the degree of circularity is obtained in the same way as shown in Fig. 6 (b). These values are used with the sum of wave areas to judge whether the liver is normal.

In this study we test only 3 slice images out of 17 slice images of a case. That's because about 3 to 4 slice images show a distinct wave pattern. By using these two measures, we establish the method to differentiate the images with liver cirrhosis from those with a normal liver. If the total sum of wave areas of the spleen is more than 1000 pixels and the average circularity of waves is more than 20%, this case corresponds to liver cirrhosis. And if the average circularity of waves is more than 35% for the area sum of 700 to 1000 pixels, the case still corresponds to liver cirrhosis. Otherwise, the case is the normal liver. Here, the used threshold values are determined by examining abdominal CT images of 32 cases: 16 cases with normal livers and 16 cases judged liver cirrhosis.

3. Experimental Results

For experiment, we use the abdominal CT images of 32 cases, which are not used in determining the threshold values. The data consist of 16 cases with normal livers and 16 cases judged liver cirrhosis. Each case consists of 17 slice images, and the resolution of each slice is 512×512. Table 1 shows the diagnostic results for the 16 liver cirrhosis cases and 16 normal liver cases by using the conventional and proposed methods. It can be notice in the table that it is possible to judge the splenic enlargement accompanied by liver cirrhosis by applying the proposed automatic method for abdominal CT images.

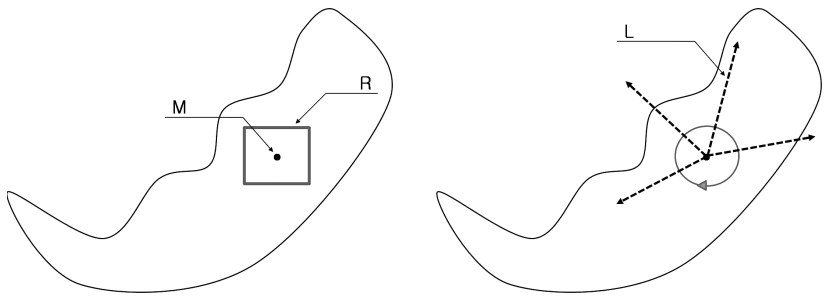

(a) (b)

Fig. 3 Segmentation of the spleen. (a) Center point M and ROI rectangle R. (b) Measuring the gray value of the pixels from M to 360 degree angle lines. Where L is one of the angle lines.

Table 1 Diagnostic results using an existing and the proposed methods for 32 cases.

Diagnosis method	16 cases judged normal liver		16 cases judged liver cirrhosis	
	Correct decision (# of cases)	Accuracy	Correct decision (# of cases)	Accuracy
Conventional*	14	87.1%	8	50.0%
Proposed	16	100 %	15	93.7%

* Based on the measurement of spleen size.

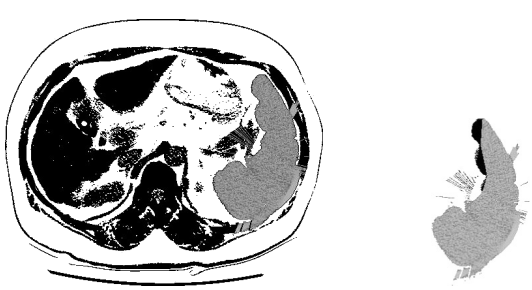

(a) (b)

Fig. 4 (a) Segmentation result of a spleen. (b) 3 distinctive waves in the segmented spleen.

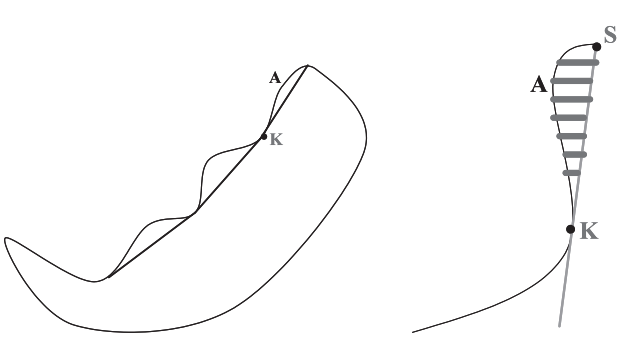

(a) (b)

Fig. 5 Wave area test. (a) Abstraction of wave parts and (b) wave area A corresponding to the first wave.

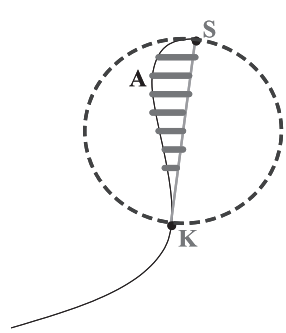

(a)

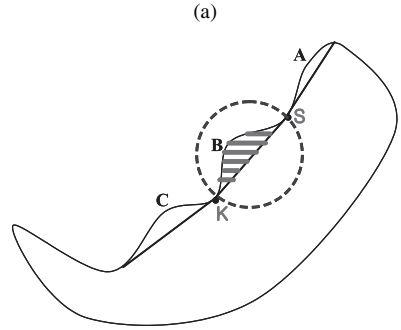

(b)

Fig. 6 Circularity test. (a) A circle surrounding area A. Its diameter is the distance between points S and K. (b) The degree of circularity of the second wave.

4. Conclusions

We propose an effective and automatic method to diagnose and detect the splenic enlargement due to abdomen abnormality. An automatic method is proposed to detect splenic enlargement by using the wave pattern of the spleen in abdominal CT images. This method is based on the fact that the abnormal abdomen produces a distinctive wave pattern on the splenic boundary, even though the spleen size is in the normal range. Instead of examining the spleen size

as in the conventional method, the proposed method tests the wave pattern to judge whether the abdomen has splenic enlargement.

References

[1] E. Torres, L. Hitmire, M. Gedgaudas, and M. Bernardino, "Computed tomography of hepatic morphologic changes in cirrhosis of the liver," J. Comput. Assist. Tomogr., vol.10, no.1, pp.47–50, 1986.

[2] P. Lamb, A. Lund, R. Kanagasabay, A. Martin, J. Webb, and R. Reznek, "Spleen size: How well do linear ultrasound measurements correlate with three-dimensional CT volume assessments?," Br. J. Radiol., vol.75, no.895, pp.573–577, 2002.

[3] P. Prassopoulos and D. Cavouras, "CT assessment of normal splenic size in children," Acta Radiol., vol.35, no.2, pp.152–154, 1994.

[4] P. Prassopoulos, M. Daskalogiannski, M. Raissaki, A. Hatjidakis, and N. Gourtsoyiannis, "Determinance of normal splenic volume on computed tomography in relation to age, gender and body habitus," Eur. Radiol., vol.7, no.2, pp.246–248, 1997.

[5] A. Schlesinger, C. Hildebolt, M. Siegel, and T. Pilgrim, "Splenic volume in children: Simplified estimation at CT," Radiology, vol.193, no.2, pp.578–580, 1994.

[6] R. Groell, L. Machan, G.J. Schaffler, M. Uggowitzer, and K.H. Peichel, "Morphometric measurement of abdominal organs: Comparison of ultrasound and spiral CT," Acta Radiol., vol.38, no.6, pp.982–985, 1997.

[7] H. Rosenberg, R. Markowitz, H. Kolberg, C. Park, A. Hubbard, and R. Bellah, "Normal splenic size in infants and children: Sonographic measurements," Am. J. Roentgenol., vol.157, no.1, pp.119–121, 1991.

[8] S. Sheth, S. Mani, H. Tamhankar, and P. Mehta, "Spleen size in health and disease: A sonographic assessment," J. Assoc. Physicians India, vol.43, no.3, pp.182–184, 1995.